

This author's accepted manuscript may be used for non-commercial purposes in accordance with [Wiley Terms and Conditions for Self-Archiving](#).

The full details of the published version of the article are as follows:

TITLE: Improved diagnostic criteria for digital flexor tendon sheath pathology using contrast tenography

AUTHORS: Kent, A V; Chesworth, M J; Wells, G; Gerdes, C; Bladon, B M; Smith, R K W; Fiske-Jackson, A R

JOURNAL: EQUINE VETERINARY JOURNAL

PUBLISHER: Wiley

PUBLICATION DATE: 20 August 2019

DOI: <https://doi.org/10.1111/evj.13166>

## Improved diagnostic criteria for digital flexor tendon sheath pathology using contrast tenography

A. V. Kent<sup>\*1</sup>, M. J. Chesworth<sup>2</sup>, G. Wells<sup>2</sup>, C. Gerdes<sup>3</sup>, B. M. Bladon<sup>4</sup>, R. K. W. Smith<sup>2</sup> and A. R. Fiske-Jackson<sup>2</sup>

<sup>1</sup>Peterson and Smith Equine Hospital, Ocala, Florida, USA; <sup>2</sup>Royal Veterinary College Equine Referral Hospital, London, UK; <sup>3</sup>Rossgates Diagnostic Centre, Newmarket, Suffolk, UK and <sup>4</sup>Donnington Grove Veterinary Group, Newbury, Berkshire, UK.

\*Corresponding author email: [akent@petersonsmith.com](mailto:akent@petersonsmith.com)

Current address for Dr Wells: Willows, Birmingham, UK.

Current address for Dr Gerdes: Pferdeklinik Hockmoor, Gescher, Germany

**Keywords:** horse; contrast tenography; digital flexor tendon sheath; manica flexoria; deep digital flexor tendon; palmar/plantar annular ligament

## Summary

**Background:** Pathology of the digital flexor tendon sheath is a significant cause of lameness in the horse. Imaging is important to identify lesions and inform on prognosis prior to tenoscopic surgery.

**Objectives:** To use a large population to evaluate 1) the sensitivity and specificity of digital flexor tendon sheath (DFTS) contrast radiographs in diagnosing manica flexoria (MF) tears, deep digital flexor tendon (DDFT) tears and constriction of the palmar/plantar annular ligament (PAL) using novel criteria; 2) predisposition to pathology in signalment and limb affected.

**Study design:** Multicentre retrospective cohort study.

**Methods:** The medical records of 206 horses with lameness localised to the DFTS, contrast radiographs and subsequent tenoscopic surgery were reviewed. Breed and limb predispositions were evaluated for pathology of the DDFT, MF and PAL constriction. Contrast radiographs of the DFTS were reviewed by four masked operators and for each pathology the sensitivity, specificity and interobserver variability were calculated.

**Results:** Contrast tenography was a sensitive test for MF tears (92% confidence interval 88.4-94.4%; specificity 56%, CI 51.1-61.1%) and specific for diagnosing DDFT tears (73%, CI 68.6-76.8%; sensitivity 54%, CI 47.8-60.2%) but had a lower sensitivity (71%, CI 65.1-75.9%) and specificity (45%, CI 39.1-52.0%) for PAL constriction. It had good to substantial interobserver agreement for MF and DDFT tears (Krippendorff's alpha 0.68 and 0.48 respectively). Ponies (57%) and cobs (58%) were significantly more likely to be affected with MF tears (other breeds 20-39%,  $p = 0.003$ ) and Thoroughbreds (50%), warmbloods (45%) and draught breeds (48%) were more likely to have DDFT tears (other breeds 22-34%,  $p = 0.01$ ). MF tears and PAL constriction were overrepresented in the hindlimbs compared to DDFT tears in forelimbs.

**Main limitations:** No standardisation of contrast radiographs was possible. The subjectivity of diagnosis of PAL constriction may also have led to bias. Radiographs were read as JPEGs reducing ability to manipulate images.

**Conclusions:** Contrast radiography of the DFTS is accurate in the pre-operative diagnosis of DFTS pathologies. Different pathologies are overrepresented in certain breeds and limbs.

## **Introduction**

The digital flexor tendon sheath (DFTS) extends from the distal metacarpus/metatarsus to the foot and contains the superficial (SDFT) and deep (DDFT) digital flexor tendons plus the accompanying manicae, vinculae and mesotenons. In the region of the metacarpo-/metatarso-phalangeal joint, the fetlock canal is bordered dorsally by the intersesamoidean ligament and palmarly/plantarly by the palmar/plantar annular ligament (PAL) [1].

Pathology of the DFTS is a significant cause of lameness with the most common lesions recorded as border tears of the DDFT and manica flexoria (MF) tears in the fetlock canal [2-5]. Specific pathologies and breed predilections have been reported; DDFT tears occurred more commonly in forelimbs in showjumpers [5] while MF tears occurred predominantly in the hindlimbs in ponies and cobs [4]. The prognosis for these lesions varies, with tears of the MF having a favourable prognosis of 79% returning to previous use following resection under tenoscopic guidance, whereas tears of the DDFT respond less favourably to tenoscopic debridement with only 38-42% returning to their previous level of work [2,4,5]. Therefore, obtaining an accurate pre-surgical diagnosis allows informed discussions regarding the prognosis for return to work.

Ultrasonography and contrast tenography are important in assessment of the DFTS following diagnostic analgesia [6]. However, ultrasound has been reported to have limited sensitivity and specificity in identifying lesions within the DFTS [3,7], particularly with regards to MF tears with a sensitivity of 38% and specificity of 92% [2] and DDFT tears with a specificity of 76% and sensitivity of 63% [5]. The use of ultrasonography has also been described in assessing and diagnosing PAL constriction, although the efficacy was not assessed, four types of constriction syndromes were described [8]. In thick skinned breeds, accuracy of ultrasound evaluation is compromised due to poor image quality, and overall accuracy of ultrasound diagnosing lesions is highly operator dependent. Contrast tenography, performed at the same time as intrathecal analgesia was first described by Hago and Vaughan [9,10] as an aid in identifying lesions in the DFTS. More recently a smaller study found contrast tenography predicted MF tears with a sensitivity of 96% and a specificity of 80% [6]. In

contrast, DDFT tears were predicted with only a sensitivity of 57% and specificity of 84% [6]; constriction by the PAL was not assessed.

The aim of this study was to define more specific criteria for intra-thecal tendon pathology and to test the hypotheses that these additional criteria will improve sensitivity and specificity of the procedure, and that obliquity and incomplete weight bearing would not affect this sensitivity and specificity.

## **Materials and Methods**

### Case Selection

Medical records from the Royal Veterinary College Equine Referral Hospital, Donnington Grove Equine Hospital and Rossdales Equine Hospital between January 2009 and July 2016 were reviewed. Cases were included if lameness was localised to the DFTS and both contrast radiography and subsequent tenoscopy was performed to confirm the following three diagnoses: MF tear, DDFT tear, and PAL constriction. Age, breed, sex, weight, leg affected, results of the clinical and lameness examination, and treatments, where available, were recorded.

### Contrast tenography

This was performed as described previously [6]. Briefly, 5-7 mls of sodium meglumine diatrizoate (Urografin 370)<sup>a</sup> or Iohexol (Omnipaque 240)<sup>b</sup> were injected with mepivacaine hydrochloride (10 ml; Intraepicaine<sup>c</sup>) aseptically into the affected DFTS via a 20-gauge 2.5 cm needle usually introduced into the distal pouch between the proximal and distal digital annular ligaments in the pastern region, although some surgeons preferred to use the proximolateral pouch for injection. The horse was walked for 4–5 strides to distribute the contrast medium within the DFTS before a lateromedial radiograph of the distal limb, to include the proximal and distal extremities of the DFTS, was obtained. All radiographs were converted to JPEG format for review.

## Anatomical study

To better define the normal position of the MF, tenograms from 13 horses (5 geldings and 4 mares; 10 forelimbs and 6 hindlimbs; 4 Thoroughbred crosses, 3 Warmbloods, 2 Welsh Section D, one Welsh Section D cross, one Irish sports horse, one Irish draught and one Arab cross) with no abnormalities of the MF (defined by tenoscopic examination) were analysed. In addition, tenograms from 4 cadaver limbs of variable breeds euthanised for reasons unrelated to lameness, were each radiographed three times, a lateromedial radiograph was taken followed by dorso $5^{\circ}$ latero-palmar/plantaromedial oblique and palmar/plantaro $5^{\circ}$ lateral-dorsomedial oblique. The two five-degree oblique views were acquired to allow comparison with the true lateromedial view for each limb. After the radiographic series was performed limbs were dissected to assure normal DFTS anatomy.

On the JPEG images, the distance of the most distal border of the MF was defined by measuring the distance between a line perpendicular to third metacarpal/tarsal bone at both the level of the proximal border of the proximal sesamoid bones (PSB) and the proximal limit of the sagittal ridge, and at the distal border of the MF (Fig 1). If the tenograms were not exact lateromedial projections and therefore the proximal border of the PSB were not aligned, the difference between the proximal margins of the PSB was split. To standardise across horse size and the use of JPEGs, the distance was expressed as a percentage of the width of the third metacarpus/metatarsus at the level of the proximal limit of the sagittal ridge. The fetlock angle was measured by drawing a line along the dorsal aspect of the third metacarpal/tarsal bone and a second line along the dorsal aspect of the first phalanx; the angle was taken where these two lines intersect.

## Sensitivity and specificity

Determination of sensitivity and specificity of the contrast tenograms was calculated after 4 evaluators (1 board certified surgeon, 2 equine surgery residents and 1 radiology resident) independently reviewed the radiographs and diagnosed the lesions seen. They were masked to case details including signalment, limb affected, clinical history and tenoscopic findings. The diagnostic criteria (Fig 2) for MF and DDFT pathology and PAL constriction with sample radiographs were given to each evaluator. Only binary outcomes (yes or no) were allowed for each criterion (Fig 2). Examples of the

diagnostic criteria are shown in Figure 3 and a normal contrast tenogram is depicted in Figure 4. If the radiograph met any one of the diagnostic criteria for MF tears or PAL constriction it was considered to have the lesion. The final sensitivity and specificity results were calculated from the total number of true positives/negatives and false positives/negatives diagnosed from all reviewers. Radiographic quality was assessed by each reviewer individually and the criteria are shown in Figure 2.

#### Tenoscopic evaluation

Information on tenoscopic findings were extracted from the medical record. Tenoscopic evaluation of the affected DFTS was performed on all cases under general anaesthesia with the horse in dorsal or lateral recumbency depending on surgeon preference. The limbs were usually exsanguinated with an Esmarch bandage placed at the distal antebrachium or crus before being aseptically prepared. A 4 mm 25-30 degree forward oblique arthroscope was introduced between the PAL and proximal digital annular ligament, as previously described [11]. The PAL was transected under tenoscopic guidance routinely or as a result of difficulty in advancing the arthroscope through the fetlock canal (surgeon preference). The proximal and distal pouches of the DFTS were explored and pathological lesions were recorded as a DDFT tear, MF tear (complete or partial) and PAL constriction. PAL constriction was diagnosed if the surgeon encountered difficulty advancing the endoscope through the fetlock canal due to insufficient space. Any concurrent lesions were also recorded.

#### Data analysis

Independent sample t-tests were used to compare the MF position in the distal limb in relation to the PSB and distal sagittal ridge using the percentage width values in hindlimbs and front limbs for the anatomical study. A Pearson chi-square test was used to analyse associations between tenoscopic findings and distribution between limbs, breed and hospital. P values  $\leq 0.05$  were considered significant. No multiple comparison correction on the P values was performed [12].

The sensitivity and specificity of contrast tenography for diagnosis of MF, DDFT and PAL lesions were calculated considering tenoscopic findings as the gold standard. Where more than one diagnostic criterion lead to a specific diagnosis, the sensitivity and specificity of each criterion were also

determined. The sensitivity and specificity were calculated for all contrast radiographs that were diagnostic or partially diagnostic and then repeated excluding the poor-quality radiographs. Presence of a complete or partial tear of the MF tear, were analysed to see if the sensitivity and specificity of the test was affected. Confidence intervals (CI) were calculated at 95%. Interobserver variability was assessed using Krippendorff's Alpha and Fleiss' Kappa coefficients. Statistical tests were performed with SPSS Statistics for Windows Version 22<sup>d</sup>.

## **Results**

### Anatomical study

The distal limit of the MF was found to be distal to the apices of the PSB and the sagittal ridge by approximately 20 mm and 30 mm respectively (Supplementary Item 1). This corresponded to approximately one third of the width of the third metacarpus and half of the third metatarsus respectively. There were no significant anatomical differences between hind and forelimbs. Obliquity of the radiograph (data not shown) produced no subjective difference in the MF positional measurements. There was a small effect of fetlock angle on the distal position of the MF, with increasing extension of the fetlock (reduced fetlock angle) resulting in a more distal location of the MF (Fig 5).

### Retrospective Clinical Study

Two hundred and six cases met the inclusion criteria consisting of 115 mares, 87 geldings and 4 stallions. The median weight was 545 kg (range 282-854 kg), with an average age of 13 years (range 3-24 years old). The breed was recorded in 196 cases and consisted of 65 cobs, 31 draughts or draught crosses, 47 ponies, 20 Thoroughbreds and 33 warmbloods. There were 168 hindlimb (80 left hind, 88 right hind) and 38 forelimb (19 left front, 19 right front) lesions, of which 33 were bilateral cases (10 cases with bilateral contrast radiographs). A total of 16 surgeons performed the tenoscopies and diagnosed the lesions.

Lesions occurred separately or in combination; the most frequent lesions described tenoscopically were a combination of MF tears and PAL constriction (55 cases). There was a significantly unequal



distribution of lesions between breeds (Table 1); cobs and ponies had a higher percentage of MF tears ( $p = 0.003$ ) and PAL constriction ( $p < 0.001$ ) in contrast to Warmbloods and Thoroughbreds. Deep digital flexor tendon tears were seen in a higher proportion of Thoroughbreds, Warmbloods and Draught horses compared to Ponies and Cobs ( $p = 0.01$ ). Hindlimbs in this population were affected with a significantly higher proportion of MF tears ( $p < 0.001$ ) and PAL constriction ( $p = 0.003$ ) (Table 1) compared to DDFT tears which were more frequently identified in the forelimbs ( $p < 0.001$ ).

When all cases were included and using a positive finding for at least one of the diagnostic criterion relevant to the diagnosis, contrast tenography had highest sensitivity (92%, CI 88.4-99.4%; specificity 56%, CI 51.1-61.1%) for diagnosis of MF tears and highest specificity for diagnosis of DDFT tears (73%, CI 68.6-76.8%; sensitivity 54%, 47.8-60.2%); while its ability to diagnose PAL constriction was only average (sensitivity 71%, CI 65.1-72.6%; specificity 45%, CI 39.1-52.0%). The sensitivity (but not the specificity) of diagnosing MF tears improved to 97% (CI 93.7-98.4%; specificity 56%, CI 51.1-61.1%) if the tear was complete.

In total 68 of cases were excluded due to poor diagnostic quality. Reasons were inadequate radiographic quality (11 with poor exposure), inadequate distribution of contrast (18 subcutaneous injections; 18 with diffusely faint contrast material, 23 with poor diffusion of contrast medium proximally or distally) and inappropriate limb positioning (7 oblique, one non weightbearing view). Re-evaluation of sensitivity and specificity after these cases were excluded (Table 2), resulted in an improvement in sensitivity of diagnosis of DDFT lesions, increasing to 62% (CI 54.9-69.2%; specificity 70%, CI 64.9-74.6%) and in the specificity of diagnosis of MF lesions, increasing to 64% (CI 57.8-69.3%; sensitivity 92%, CI 88.1-95%).

As shown in Table 2, the criterion based on identification of an isolated area of contrast overlying the dorsal border of the DDFT at the level of the MF (criterion 4), had the poorest sensitivity and specificity for diagnosing MF tears. When this diagnostic criterion is excluded the revised sensitivity and specificity for contrast tenograms diagnosing MF tears is 85% (CI 81.1-88.9%) and 72% (CI 67.5-76.9%) respectively.

There was substantial interobserver agreement between all four evaluators for MF tears, which improved to near perfect agreement for MF tears after excluding diagnostic criterion 4 (isolated area of contrast in the region of the MF), which can be seen in Table 3. There was also substantial

agreement between observers when diagnosing DDFT tears. However, there was poor agreement between evaluators when diagnosing PAL constriction from the contrast radiographs.

## **Discussion**

This study demonstrated high sensitivity of contrast tenography in diagnosing MF tears, and moderate specificity in determining if a horse has a DDFT tear. However, the technique lacked sensitivity and specificity for determining PAL constriction.

The key requirements for performing a contrast tenogram are accurate injection into the DFTS (improved by the selection of reliable injection sites), adequate distribution (improved by walking the horse), appropriate exposure (improved with the use of digital equipment), a lateromedial radiograph (although minor obliquity does not alter the parameters significantly) and fetlock extension (normally loaded limb). This study showed a relationship between the MF position and fetlock angle which may explain why hindlimbs are more commonly affected than forelimbs (hind fetlocks are more extended than those in the forelimbs [13,14]); this is consistent with a hypothesised pathogenesis for MF tears where a more distal MF position (associated with conformational abnormality or overloading of the limb) is more at risk of getting caught on the proximal scutum and being torn.

Analysing each criterion allows assessment of each of their individual value in the diagnosis of lesions. The fourth criterion, an isolated area of contrast on the dorsal border of the DDFT, which has previously been suggested as an indication of a MF tear [6], had inferior sensitivity and specificity comparatively to the other MF tear criteria. Therefore, excluding this criterion improved the specificity of the test with only a slight reduction in sensitivity. Interestingly, two parallel contrast lines delineating the MF was the most specific criterion whereas displacement of the distal end of the MF proximal to the level of the sesamoids was the most sensitive criterion. This extra criterion was based of the anatomical study which confirmed the normal position of the MF to be significantly lower than the apices of the PSB (approximately 20 mm). It is likely that more complete disruption of the attachments of the MF results in greater proximal displacement of the MF on the contrast tenograms thereby improving the likelihood they are detected (improved sensitivity of the test).

Deep digital flexor tendon tears were most commonly missed on contrast tenograms. Non-detection of a DDFT tear in the contrast tenograms seemed to occur more commonly when the contrast medium was faint through the fetlock canal; this could have been the result of an over-extended fetlock (closing the defect), PAL constriction, or poor contrast diffusion. Superimposition of the PSB over the region where DDFT tears are detected likely explains the reduced sensitivity of this criterion. False negatives for DDFT tears were also seen when the tear was masked by particularly outpouchings of the sheath between the PAL and proximal digital annular ligament. Thick legs, in cob breeds especially, had increased opacity of the soft tissues resulting in poorer contrast with the contrast medium which likely affected the sensitivity of the test for diagnosing DDFT tears.

Contrast tenography of the DFTS showed poor sensitivity and specificity when used to diagnose PAL constriction. PAL constriction was the most commonly diagnosed lesion and frequently occurred in combination with other lesions. Furthermore, this diagnosis is more subjective than tears in the DDFT or MF and is usually diagnosed if it is deemed difficult to pass the endoscope through the fetlock canal. Some surgeons routinely transect the PAL or when complex tenosynovitis is diagnosed [15] whereas others will only perform a desmotomy if there is constriction preventing easy passage of the arthroscope. This likely results in overdiagnosis of PAL constriction if performance of a desmotomy during surgery is considered de facto presence of constriction. It would seem intuitive that more contrast in the fetlock canal would indicate less constriction but objectively measuring this is challenging.

Other modalities are used to image the DFTS but limitations exist amongst them all. Ultrasonography is typically the imaging method of choice but with thick skinned horses, such as cobs where MF tears are common, the diagnostic quality of the ultrasonography is compromised. Furthermore, ultrasonography is frequently operator-dependent, requiring several views, whereas in this study we have demonstrated substantial to near perfect user agreement with interpretation of contrast tenograms. The degree of interobserver agreement was very good for diagnosing both MF and DDFT tears from contrast tenograms indicating that interpretation is consistent between different observers.

Computed tomography (CT) and contrast CT of the DFTS have been described in cadaver limbs. This requires expensive equipment unavailable to some practitioners and usually requires general anaesthesia [16,17]. In addition, the sensitivity and specificity of CT in diagnosing MF and DDFT tears

has yet to be described. Magnetic resonance imaging (MRI) has been used widely to investigate lameness associated with the foot and distal limb; lesions of the DDFT, SDFT, MF and sesamoidean ligaments have been described but many intra-thechal flexor tendon changes were described as subtle [18]. As with CT, this modality requires expensive equipment not available to some practitioners and high-field MRI, which gives the best quality views necessary to identify these lesions, also requires general anaesthesia.

This study found a breed predisposition for cobs which is similar to the other UK study [4] but differs from the study of Arensburg *et al.* [5] which consisted predominantly of warmbloods. The current study is the largest of its size, including three hospitals with a varied case population, and provides an accurate representation of the general horse population in the UK. The limb predisposition seen in this study, with PAL constriction and MF tears seen more commonly in hindlimbs, and DDFT tears more commonly encountered in the front limbs, is consistent with several previous studies [2-4,7,15]. PAL constriction more commonly occurring in hindlimbs has been reported in a recent study [19] and was attributed to a change in force due to the PSB more distal location during increased fetlock hyperextension and propulsive force contribution compared to the forelimbs.

The limitations of this study include use of JPEG format for review of the tenograms. This was performed for logistical reasons to allowing reading of the large number of cases in a masked fashion. We used tenoscopic findings as the gold standard. As this is a retrospective study with multiple surgeons involved, diagnosing a subjective lesion without prior definitions may lead to over or underdiagnosis during tenoscopy; this will especially have affected the sensitivity and specificity of contrast tenograms in the diagnosis of PAL constriction.

While contrast tenography of the DFTS does not delineate other structures associated with DFTS well, the relative ease and cost, especially when combined with another diagnostic procedure (diagnostic analgesia), along with the high sensitivity of the tests capacity to aid in diagnosing MF tears, strongly supports the technique as a valuable clinical tool.

In conclusion, this extensive retrospective study has demonstrated that contrast tenography of the DFTS is an accurate diagnostic aid assisting in clinical decision making, especially with the novel radiographic interpretation criteria used in this study. It was more robust in diagnosing MF tears compared with DDFT tears and PAL constriction, which makes it a good complementary diagnostic

procedure to ultrasonography. Including new criteria assessing whether the dorsal MF line tapers at the PSB and analysing the degree of PAL constriction has given us a new way to interpret contrast tenograms.

#### **Authors' declarations of interest**

No competing interests have been declared.

#### **Ethical animal research**

Research ethics committee oversight not required for this journal: a retrospective analysis of clinical data.

#### **Owner informed consent**

Explicit owner informed consent for inclusion of animals in the retrospective clinical study was not stated.

Cadaveric limbs obtained from a commercial abattoir.

#### **Sources of Funding**

None

#### **Acknowledgements**

We thank Rhiannon Morgan and Nicola Lynch for interpreting radiographs and Yu-Mei Chang for statistical analysis support.

#### **Authorship**

All authors provided substantial contributions to conceptions and design of the manuscript as well as drafting the article, revising it critically and giving final approval.

## Manufacturers' addresses

<sup>a</sup>BerliMed S.A, Madrid, Spain.

<sup>b</sup>GE Healthcare AS, Oslo, Norway.

<sup>c</sup>Dechra Ltd., Skipton, North Yorkshire, UK.

<sup>d</sup>IBM Corporation, Armonk, New York, USA.

## Table legends

**Table 1:** Lesion distribution between breeds and limb affected. \*percentage of cases affected with MF tears are significantly higher in these breeds; <sup>φ</sup>percentage of cases affected with DDFT tears are significantly higher in these breeds; <sup>†</sup> percentage of cases affected with PAL constriction are significantly higher in these breeds

| Breed        | MF tear     |                 |                         | DDFT tear         |                 |                         | PAL constriction     |                 |                         | Total (n) |
|--------------|-------------|-----------------|-------------------------|-------------------|-----------------|-------------------------|----------------------|-----------------|-------------------------|-----------|
|              | Present (n) | Not present (n) | Percentage affected (%) | Present (n)       | Not present (n) | Percentage affected (%) | Present (n)          | Not present (n) | Percentage affected (%) |           |
| Cob          | 38          | 27              | 58*                     | 14                | 51              | 22                      | 46                   | 19              | 71 <sup>†</sup>         | 65        |
| Draught      | 12          | 19              | 39                      | 15                | 16              | 48 <sup>φ</sup>         | 17                   | 14              | 55                      | 31        |
| Pony         | 27          | 20              | 57*                     | 16                | 31              | 34                      | 33                   | 14              | 70 <sup>†</sup>         | 47        |
| Thoroughbred | 4           | 16              | 20                      | 11                | 9               | 50 <sup>φ</sup>         | 7                    | 13              | 35                      | 20        |
| Warmblood    | 10          | 23              | 30                      | 15                | 18              | 45 <sup>φ</sup>         | 10                   | 23              | 30                      | 33        |
| Total        | 91          | 105             |                         | 71                | 125             |                         | 113                  | 83              |                         | 196       |
| P value      | 0.003*      |                 |                         | 0.01 <sup>φ</sup> |                 |                         | <0.0001 <sup>†</sup> |                 |                         |           |
| <b>Limb</b>  |             |                 |                         |                   |                 |                         |                      |                 |                         |           |
| Forelimb     | 2           | 36              | 5                       | 27                | 11              | 68                      | 14                   | 24              | 37                      | 38        |
| Hindlimb     | 96          | 72              | 57                      | 45                | 123             | 27                      | 106                  | 62              | 63                      | 168       |
| Total        | 98          | 108             |                         | 72                | 134             |                         | 120                  | 86              |                         | 206       |
| P value      | P<0.0001    |                 |                         | P<0.0001          |                 |                         | 0.003                |                 |                         |           |

**Table 2:** The sensitivity and specificity of contrast tenograms using each criterion described in Figure 1 and cumulatively after exclusion of poor-quality radiographs. MF = manica flexoria; DDFT = deep digital flexor tendon; DFTS = digital flexor tendon sheath; PAL = palmar/plantar annular ligament.

|                                | <b>Criteria</b>  | <b>Lesion</b>    | <b>Sensitivity %<br/>(confidence interval)</b> | <b>Specificity %<br/>(confidence interval)</b> |
|--------------------------------|--|------------------|--|--|
| Individual criteria assessment | 2. Are there 2 parallel lines visible delineating the MF, just proximal to the proximal sesamoid bones at the dorsal border of the DDFT?   | MF tear          | 66 (61.2-71.4)                                 | 85 (80.9-88.2)                                 |
|                                | 3. Does the most dorsal of the parallel lines extend distally to meet or overlie the proximal border of the proximal sesamoid bones?   | MF tear          | 83 (78.6-86.8)                                 | 72 (67.8-76.8)                                 |
|                                | 4. Is there an isolated area of contrast overlying the dorsal border of the DDFT at the level of the MF?   | MF tear          | 40 (35.1-45.7)                                 | 68 (63.1-72.8)                                 |
|                                | 5. Is there a thin line of contrast extending proximally and obliquely from the outpouching of the DFTS, distal to the proximal sesamoid bones, coursing within the outline of the DDFT? | DDFT tear        | 54 (47.8-60.2)                                 | 73 (68.6-76.8)                                 |
|                                | 6. Is there equal distribution of contrast in the DFTS, proximal and   | PAL constriction | 56 (50.6-60.4)                                 | 58 (52.4-63.5)                                 |

|  |  |                             |                            |                            |
|--|--|-----------------------------|----------------------------|----------------------------|
|  | distal to the proximal sesamoid bones and at the level of the proximal sesamoid bones?                                       |                             |                            |                            |
|  | 7. Is there normal soft tissue contour of the palmar/plantar aspect of the limb at the level of the proximal sesamoid bones? | PAL<br>constriction         | 45 (39.8-<br>50.4)         | 59 (53.3-<br>65.2)         |
|  |  |                             |                            |                            |
| <b>After exclusion<br/>of poor-quality<br/>radiographs</b> |  | <b>MF tears</b>             | <b>92 (88.1-<br/>95.0)</b> | <b>64 (57.8-<br/>69.3)</b> |
|  |  | <b>DDFT tears</b>           | <b>62 (54.9-<br/>69.2)</b> | <b>70 (64.9-<br/>74.6)</b> |
|  |  | <b>PAL<br/>constriction</b> | <b>65 (58.6-<br/>71.8)</b> | <b>49 (41.9-<br/>56.6)</b> |

**Table 3:** Interobserver agreement analysis of the four evaluators diagnosing manica flexoria (MF) tears, deep digital flexor tendon (DDFT) tears and palmar/plantar annular ligament (PAL) constriction from the contrast radiographs. No agreement (0.01-0.20), Poor Agreement 0.21-0.40, Fair agreement 0.41-0.60, Substantial agreement 0.61-0.80, Near perfect agreement >0.80.

|                      | MF tear | MF tear<br>(excluding<br>criteria 4) | DDFT tear | PAL<br>constriction |
|----------------------|---------|--------------------------------------|-----------|---------------------|
| Krippendorff's Alpha | 0.68    | 0.79                                 | 0.46      | 0.11                |
| Fleiss' Kappa        | 0.69    | 0.81                                 | 0.49      | 0.13                |



## Figure legends

**Fig 1:** Measurements for the normal manica flexoria (MF) position in a lateromedial contrast tenogram. (A) shows the measurements made for the distance from the apices of the proximal sesamoid bones to the distal border of the MF; (B) shows the measurement between the proximal limit of the palmar/plantar sagittal ridge and the distal border of the MF. The double-headed arrow over the third metacarpus/metatarsus is the measurement used to standardise the distances between horses and radiographs.

**Fig 2:** Flow chart for diagnosis of a manica flexoria tear, deep digital flexor tendon tear and PAL constriction; MF = manica flexoria; DDFT = deep digital flexor tendon; DFTS = digital flexor tendon sheath; PAL = palmar/plantar annular ligament

**Fig 3:** Examples of contrast radiographs demonstrating diagnostic criteria used for assessment: a) the two parallel lines which delineate the manica flexoria (MF) just proximal to the proximal sesamoid bones (PSB), at the dorsal border of the deep digital flexor tendon (DDFT), are not visible (arrowed). The most dorsal line is not evident; b) the most dorsal of the parallel lines does not extend distally to the proximal border of the PSB (arrowed), it tapers further proximal in the digital flexor tendon sheath (DFTS) than at the level of the PSB; c) isolated area of contrast overlying the dorsal border of the DDFT at the level of the MF (arrowed); d) thin line of contrast extending proximally and obliquely from the outpouching of the DFTS distal to the PSB, within the outline of the DDFT (arrowed); e) unequal distribution of contrast in the DFTS, proximal and distal to the PSB (arrowed); f) Irregular soft tissue contour of the palmar/plantar aspect of the limb at the level of the PSB (arrowed).

**Fig 4:** Normal digital flexor tendon sheath with adequate filling and delineation of structures including manica flexoria.

**Fig 5:** The effect of fetlock angle on manica flexoria (MF) position. MF-PSB as % of CW = Distance of the distal border of the MF from the apices of the proximal sesamoid bones expressed as a percentage of the width of the distal third metacarpus/metatarsus

MF-SR as a % of CW = Distance of the distal border of the MF from the proximal limit of the sagittal ridge of the third metacarpus/metatarsus expressed as a percentage of the width of the distal third metacarpus/metatarsus

### Supporting Information

**Supplementary Item 1:** Manica Flexoria position.

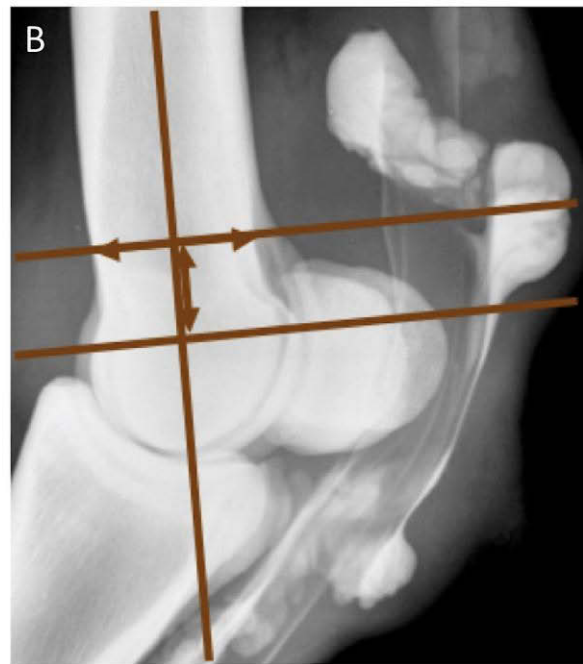
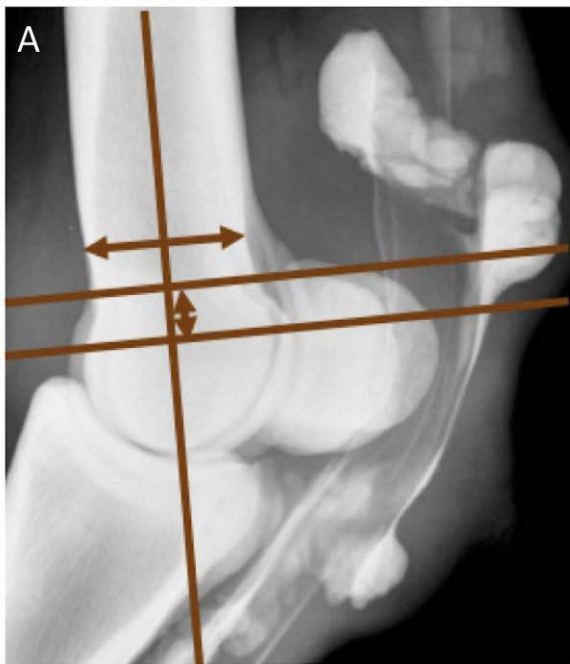
### References

1. Denoix, J.-M. (1994) Functional Anatomy of Tendons and Ligaments in the Distal Limbs (Manus and Pes). *Vet. Clin. North Am. Equine Pract.* **10**, 273-322.
2. Smith, M.R.W. and Wright, I.M. (2006) Noninfected tenosynovitis of the digital flexor tendon sheath: a retrospective analysis of 76 cases. *Equine Vet. J.* **38**, 134-141.
3. Wright, I.M. and McMahon, P.J. (1999) Tenosynovitis associated with longitudinal tears of the digital flexor tendons in horses: A report of 20 cases. *Equine Vet. J.* **31**, 12-18.
4. Findley, J.A., Oliveira, F. De and Bladon, B. (2012) Tenoscopic Surgical Treatment of Tears of the Manica Flexoria in 53 Horses. *Vet. Surg.* **41**, 924-930.
5. Arensburg, L., Wilderjans, H., Simon, O., Dewulf, J. and Boussauw, B. (2011) Nonseptic tenosynovitis of the digital flexor tendon sheath caused by longitudinal tears in the digital flexor tendons: A retrospective study of 135 tenoscopic procedures. *Equine Vet. J.* **43**, 660-668.
6. Fiske-Jackson, A.R., Barker, W.H.J., Eliashar, E., Foy, K. and Smith, R.K.W. (2013) The use of intrathecal analgesia and contrast radiography as preoperative diagnostic methods for digital flexor tendon sheath pathology. *Equine Vet. J.* **45**, 36-40.

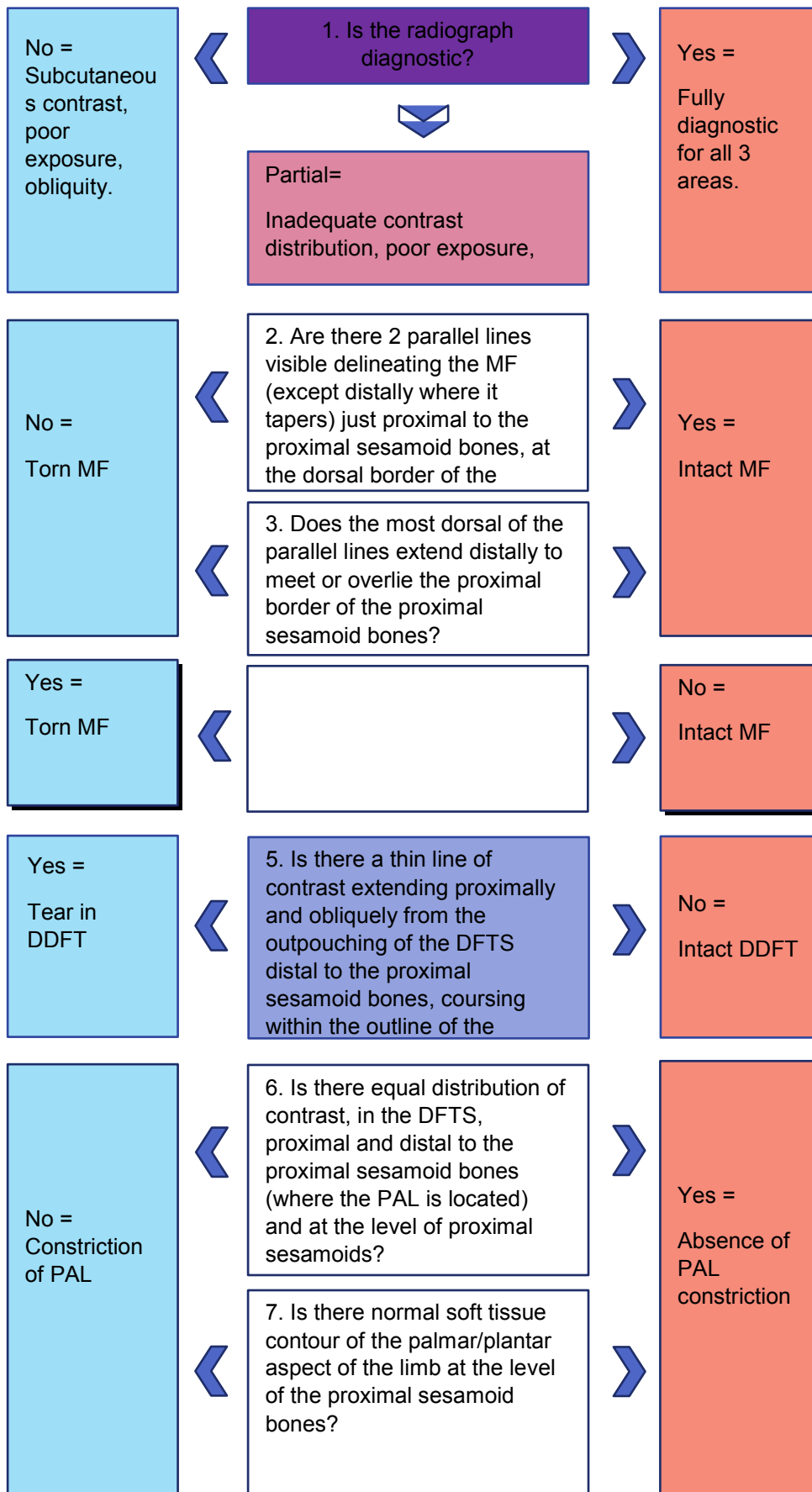
7. Fortier, L.A. (2010) Indications and techniques for tenoscopic surgery of the digital flexor tendon sheath. *Equine Vet. Educ.* **17**, 218-224.
8. Dik, K.J., Belt, A.J. and Keg, P.R. (1991) Ultrasonographic evaluation of fetlock annular ligament constriction in the horse. *Equine Vet. J.* **23**, 285-288.
9. Hago, B.E.D. and Vaughan, L.C. (1986) Use of contrast radiography in the investigation of tenosynovitis and bursitis in horses. *Equine Vet. J.* **18**, 375-382.
10. Hago, B.E. and Vaughan, L.C. (1986) Radiographic anatomy of tendon sheaths and bursae in the horse. *Equine Vet. J.* **18**, 102-106.
11. Kummerle, J.M., Theis, F. and Smith, R.K.W. (2018) Diagnosis and management of tendon and ligament disorders. In: *Equine Surgery* 5th edn. Eds: J.A. Auer, J.A. Stick. Elsevier, St Louis, Missouri. pp 1411-1444.
12. Perneger, T.V. (1998) What's wrong with Bonferroni adjustments. *Brit. Med. J.* **316**, 1236-1238
13. Back, W., Schamhardt, H.C., Savelberg, H.H., Bogert, A.J., Bruin, G., Hartman, W. and Barneveld, A. (1995) How the horse moves: 1. Significance of graphical representations of equine forelimb kinematics. *Equine Vet. J.* **27**, 31-38.
14. Back, W., Schamhardt, H.C., Savelberg, H.H., Bogert, A.J., Bruin, G., Hartman, W. and Barneveld, A. (1995) How the horse moves: 2. Significance of graphical representations of equine hind limb kinematics. *Equine Vet. J.* **27**, 39-45.
15. Fortier, L.A., Nixon, A.J., Ducharme, N.G., Mohammed, H.O. and Yeager, A. (1999) Tenoscopic Examination and Proximal Annular Ligament Desmotomy for Treatment of Equine "Complex" Digital Sheath Tenosynovitis. *Vet. Surg.* **28**, 429-435.
16. Lacitignola, L., Luca, P. De, Guarracino, A. and Crovace, A. (2015) Computed Tomographic Tenography of Normal Equine Digital Flexor Tendon Sheath: An Ex Vivo Study. *Vet. Med. Int.* 2015, 1-5.
17. Agass, R., Dixon, J. and Fraser, B. (2018) Computed tomographic contrast tenography of the digital flexor tendon sheath of the equine hindlimb. *Vet. Radiol. Ultrasound* **59**, 279-288.

18. King, J.N., Zubrod, C.J., Schneider, R.K., Sampson, S.N. and Roberts, G. (2013) MRI findings in 232 horses with lameness localized to the metacarpo(tarso)phalangeal region and without a radiographic diagnosis. *Vet. Radiol. Ultrasound* **54**, 36-47.
19. Owen, K.R., Dyson, S.J., Parkin, T.D.H., Singer, E.R., Kristoffersen, M. and Mair, T.S. (2008) Retrospective study of palmar/plantar annular ligament injury in 71 horses: 2001-2006. *Equine Vet. J.* **40**, 237-244.

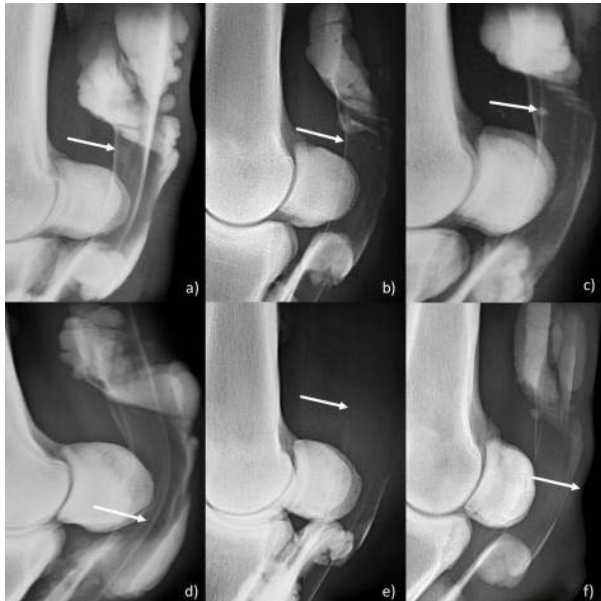**Fig 1:** Measurements for the normal manica flexoria (MF) position in a lateromedial contrast tenogram. (A) shows the measurements made for the distance from the apices of the proximal sesamoid bones to the distal border of the MF; (B) shows the measurement between the proximal limit of the palmar/plantar sagittal ridge and the distal border of the MF. The double-headed arrow over the third metacarpus/metatarsus is the measurement used to standardise the distances between horses and radiographs.



**Fig 2:** Flow chart for diagnosis of a manica flexoria tear, deep digital flexor tendon tear and PAL constriction; MF = manica flexoria; DDFT = deep digital flexor tendon; DFTS = digital flexor tendon sheath; PAL = palmar/plantar annular ligament

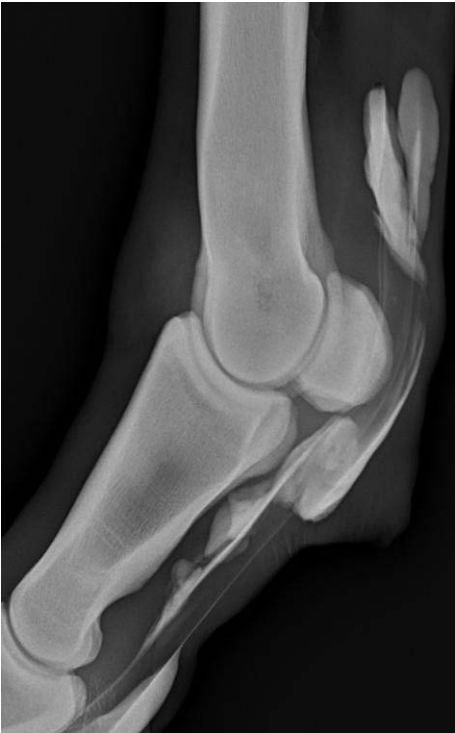

**Fig 3:** Examples of contrast radiographs demonstrating diagnostic criteria used for assessment: a) the two parallel lines which delineate the manica flexoria (MF) just proximal to the proximal sesamoid bones (PSB), at the dorsal border of the deep digital flexor tendon (DDFT), are not visible (arrowed). The most dorsal line is not evident; b) the most dorsal of the parallel lines does not extend distally to the proximal border of the PSB (arrowed), it tapers further proximal in the digital flexor tendon sheath (DFTS) than at the level of the PSB; c) isolated area of contrast overlying the dorsal border of the DDFT at the level of the MF (arrowed); d) thin line of contrast extending proximally and obliquely from the outpouching of the DFTS distal to the PSB, within the outline of the DDFT (arrowed); e) unequal distribution of contrast in the DFTS, proximal and distal to the PSB (arrowed); f) Irregular soft tissue contour of the palmar/plantar aspect of the limb at the level of the PSB (arrowed).





**Fig 4:** Normal digital flexor tendon sheath with adequate filling and delineation of structures including manica flexoria.



**Fig 5:** The effect of fetlock angle on manica flexoria (MF) position. MF-PSB as % of CW = Distance of the distal border of the MF from the apices of the proximal sesamoid bones expressed as a percentage of the width of the distal third metacarpus/metatarsus

MF-SR as a % of CW = Distance of the distal border of the MF from the proximal limit of the sagittal ridge of the third metacarpus/metatarsus expressed as a percentage of the width of the distal third metacarpus/metatarsus

