

VetRecord Case Reports

Use of subcutaneous ureteral bypass systems as a bridge to definitive ureteral repair in a cat with bilateral ureteral ligation secondary to complicated ovariohysterectomy.

Journal:	<i>Veterinary Record Case Reports</i>
Manuscript ID	vetreccr-2018-000758.R2
Manuscript Type:	Companion or pet animals
Species:	Cats
Date Submitted by the Author:	09-Apr-2019
Complete List of Authors:	Beer, Andrew; Charter Veterinary Hospital, Lipscomb, Vicky; Royal Veterinary College, Department of Veterinary Clinical Sciences Rutherford, Lynda; Royal Veterinary College, Small Animal Surgery Lee, Karla; The Royal Veterinary College, Dept of Clinical Science and Services
Keywords:	Acute Kidney Injury, Ureteral Ligation, Ureteral Injury, Subcutaneous Ureteral Bypass, Neoureterocystostomy, Emergency medicine
Topics:	Surgery, Imaging, Urology, Emergency medicine and critical care
Abstract:	A kitten presented with acute kidney injury, bilateral hydronephrosis and proximal hydroureter, three days following bilateral ureteral ligation, during a complicated ovariohysterectomy procedure. Clinical signs were anorexia, lethargy, weakness, hypothermia, nausea, pain and anuria, associated with marked azotaemia, hyperkalaemia and metabolic acidosis. Insufficient response to medical management alone, led to emergency surgical placement of bilateral subcutaneous ureteral bypass systems (SUB), resulting in dramatic improvement in azotaemia and acidosis and resolution of hyperkalaemia. Elective bilateral neoureterocystostomy was performed the next day. The cat was clinically well for three months until the left SUB cystostomy catheter migrated out of the bladder resulting in uroabdomen. At this time, fluoroscopy demonstrated normal ureteral function bilaterally, so both SUBs were removed. Following recovery from surgery the cat has remained clinically normal. This report highlights the possibility of temporary SUB placement as a bridge to definitive ureteral repair in cases of accidental ureteral ligation.

Veterinary Record casereports

TITLE OF CASE

Use of subcutaneous ureteral bypass systems as a bridge to definitive ureteral repair in a cat with bilateral ureteral ligation secondary to complicated ovariohysterectomy

SUMMARY

A kitten presented with acute kidney injury, bilateral hydronephrosis and proximal hydroureter, three days following bilateral ureteral ligation, during a complicated ovariohysterectomy procedure. Clinical signs were anorexia, lethargy, weakness, hypothermia, nausea, pain and anuria, associated with marked azotaemia, hyperkalaemia and metabolic acidosis. Insufficient response to medical management alone, led to emergency surgical placement of bilateral subcutaneous ureteral bypass systems (SUB), resulting in dramatic improvement in azotaemia and acidosis and resolution of hyperkalaemia. Elective bilateral neoureterocystostomy was performed the next day. The cat was clinically well for three months until the left SUB cystostomy catheter migrated out of the bladder resulting in uroabdomen. At this time, fluoroscopy demonstrated normal ureteral function bilaterally, so both SUBs were removed. Following recovery from surgery the cat has remained clinically normal. This report highlights the possibility of temporary SUB placement as a

1 bridge to definitive ureteral repair in cases of accidental ureteral ligation.
2
3
4

5 **BACKGROUND**

6 Ureteral ligation is a rarely reported complication of ovariohysterectomy in cats and
7 dogs with only single case reports of unilateral ureter ligation in the veterinary
8 literature¹. Nevertheless, its impact on renal function can result in significant
9 morbidity and mortality.
10

11 Complete ureteral ligation results in an acute, severe reduction in renal blood flow
12 (RBF) and glomerular filtration rate (GFR) ^{2, 3, 4}. Timely ligation reversal can result
13 in complete recovery of RBF and GFR ². Delayed ligation reversal induces renal
14 tubulointerstitial injury, leading to progressive interstitial fibrosis, tubular apoptosis
15 and chronic renal dysfunction beyond ligation reversal ^{2, 3}. In a study of 76 human
16 patients experiencing iatrogenic unilateral obstructive ureteral injury requiring
17 surgical reconstruction, a ligation reversal delay of two weeks resulted in an
18 increased risk of chronic renal dysfunction a median of 61 months after surgery ³.
19

20 Diagnosis of unilateral ureteral ligation in dogs and cats is frequently delayed with
21 reports of diagnosis five days to two years after surgery ⁵⁻¹⁰. Delay is in part due to
22 non-specific clinical signs and absence of azotaemia in animals with a normal
23 contralateral kidney. However previous veterinary reports, also reveal a variable
24 time to diagnosis of five days to seven years with bilateral ureteral ligation in dogs
25 and cats ¹¹⁻¹³.
26

27 Gold standard surgical management options for acute iatrogenic ureteral ligation,
28 with irreversible ureteral injury, are end-to-end or end-to-side ureteral anastomosis
29 ⁹ or re-implantation of the proximal cut end of the ureter into the bladder
30 (neoureterocystostomy) ^{1, 11}. Depending on loss of ureteral length, additional
31 measures may be required to extend the bladder towards the kidney, a boari flap
32 with psoas hitch ^{11, 14} and/or to move the kidney towards the bladder, renal
33 descensus ¹¹. These are advanced surgical procedures, for which microsurgical
34 instruments and magnification provided by an operating microscope or surgical
35 loupes are required ¹. Referral from first opinion practice is therefore required,
36 adding further treatment delay.
37

38 Here we report for the first time, the use of bilateral subcutaneous ureteral bypass
39 systems (SUB) as an emergency temporary measure, to decompress renal pelvis
40 dilation and limit renal tubulointerstitial injury, three days after bilateral ureteral
41 ligation in a cat. SUBs acted as a bridge to definitive repair by bilateral
42 neoureterocystostomy and limited the potential post-operative complications seen
43
44
45
46
47
48
49
50
51
52
53
54
55
56
57
58
59
60

1 with neoureterocystostomy. Long-term, SUBs were removed and the cat survived
2 with no clinical evidence of renal or ureteral dysfunction.
3
4
5

7 **CASE PRESENTATION**

8 A 2.3kg, 21-week-old, female neutered, domestic shorthaired cat underwent
9 ovariohysterectomy via a flank approach. Intraoperative haemorrhage prompted
10 conversion to a ventral midline laparotomy to address the haemorrhage. During the
11 following three days the cat was anorexic, with progressive lethargy, weakness,
12 hypothermia, nausea (licking lips), vocalisation, abdominal discomfort and lack of
13 urination and defecation, despite treatment with buprenorphine, intravenous fluid
14 therapy, mirtazapine and a heated pad. The cat presented to a referral hospital 72
15 hours after ovariohysterectomy, obtunded with bradycardia (140 beats per minute),
16 hypothermia (36.0 degrees Celsius), abdominal discomfort and muscle tremors.
17
18

23 **INVESTIGATIONS**

24 An emergency database (PhOxUltra, Nova Biomedical) revealed metabolic acidosis,
25 hyperkalaemia and severe azotaemia (Table 1). Systolic blood pressure (Doppler
26 sphygmomanometry) was normal at 130 mmHg. The cat was given 0.1 mg/kg
27 methadone (Synthadon, Animalcare) and 0.2 mg/kg midazolam (Hypnovel, Roche)
28 for diagnostic imaging. Abdominal ultrasound and bilateral pyelography, performed
29 by ultrasound-guided injection of 300 mg/ml iohexol (Omnipaque 300, GE
30 Healthcare) into the renal pelvises ¹⁵, demonstrated bilateral hydronephrosis, failure
31 of opacification of the entire right ureter and distal left ureter (Figure 1) and free
32 peritoneal fluid, consistent with bilateral proximal ureteric obstruction. Biochemical
33 analysis (Vetscan, Abaxis UK) of peritoneal fluid did not confirm uroabdomen: serum
34 and peritoneal creatinine were 1092 µmol/l and 1135 µmol/l respectively and serum
35 and peritoneal potassium were both >8.5mmol/l.
36
37
38
39
40
41
42
43
44
45
46
47
48
49
50
51
52
53
54
55
56
57
58
59
60

Table 1: Effects of medical management and surgery on results of venous blood gas analysis.

A patient-side analyser (PhOxUltra, Nova Biomedical) was used for all analyses (without sample dilution). This analyser was unable to quantify concentrations of urea greater than 35.7 mmol/l and concentrations of creatinine greater than 1768 μ mol/l. (SUB, subcutaneous ureteral bypass systems)

Venous blood analysis (reference range)	On presentation	8h after onset of medical management	8h after SUB placement	12h after neoureterocystostomy
pH (7.36-7.47)	7.018	7.122	7.330	7.403
Base excess (0 \pm 4)	-22.5	-16.4	-10.0	5.9
Bicarbonate (20-24 mmol/l)	8.8	13.1	16.2	19
Potassium (3.6-5.6 mmol/l)	11.12	10.28	4.52	4.11
Sodium (140.0-153.0 mmol/l)	139.9	140.0	165.8	160.8
Urea (3.0-10.0 mmol/l)	>35.7	>35.7	>35.7	28.6
Creatinine (50-140 μ mol/l)	>1768	>1768	389	148
Packed cell volume (24-45%)	22	-	26	26
Total solids (61-80 g/l)	52	-	82	65

DIFFERENTIAL DIAGNOSIS

- Bilateral ureteral injury/ligation secondary to complicated ovariohysterectomy¹
- Bilateral ureteral obstruction secondary to ureterolithiasis, ureteral stricture, purulent ureteral plug, dried solidified blood stones and circumcaval ureter¹⁶
- Acute kidney injury secondary to toxins (non-steroidal anti-inflammatory drugs, ethylene glycol, toxic plants)¹⁷

TREATMENT

Medical stabilisation was instigated from admission for eight hours prior to surgery. 2mg/kg furosemide (Dimazon, Intervet UK) was given intravenously. Peritoneal dialysis was performed via a 14 gauge, 20 cm fenestrated peritoneal catheter (MILA Chest Drain; MILA International). Peritoneal fluid was withdrawn and replaced with 20 ml of 2.5% glucose (Glucose, Hameln Pharmaceuticals) in Hartmanns' solution (Aqupharm 11, Animalcare). This was repeated twice with 25 ml and 50 ml of 2.5% glucose solution. 0.5 ml/kg 10% calcium gluconate (Hameln Pharmaceuticals), 0.5 ml/kg 50% glucose (Hameln Pharmaceuticals) and 0.2 IU/kg insulin (Actrapid, Novo Nordisk A/S) were given intravenously every four hours. 8.4% (1 mmol/ml bicarbonate) sodium bicarbonate (BBraun), diluted one in six in water for injection (Norbrook), was given intravenously slowly over one to three hours, three times [dose in mmol = 0.33 x (base deficit x 0.3 x body weight)]. Methadone was given as required for analgesia. Despite this treatment, hyperkalaemia, acidosis, azotaemia and anuria persisted (Table 1). Warming increased body temperature to 38.4 degrees Celsius.

Emergency exploratory laparotomy revealed multiple ligatures in the dorsal abdomen. Severe oedema and bruising of the retroperitoneal space precluded identification of the ureters without magnification. Bilateral SUBs (Norfolk Vet Products) were placed according to the manufacturer's instructions¹⁸. The abdomen was lavaged and an abdominal drain placed (Jackson Pratt silicone wound drain, Infusion Concepts). Peri-operatively, 1.5 mg/kg ropivacaine (Naropin, AstraZeneca) was given via epidural catheter every six hours and 20mg/kg amoxicillin clavulanate (Augmentin, GlaxoSmithKline) intravenously every eight hours.

Urination was seen within two hours after the first surgery and blood analysis had improved by eight hours (Table 1). Exploratory laparotomy was repeated with the aid of 2.5x magnifying loupes. Intra-operative fluoroscopy (Arcadis Varic, Siemens) with iohexol injection into SUB ports revealed contrast leak from the mid right ureter (Figure 2). Obstruction of the proximal left ureter was as noted previously. Ventral cystotomy and retrograde catheterisation of both ureters with 4-0 polypropylene (Prolene, Ethicon) revealed bilateral distal ureteral ligation. Both proximal ureteral segments were identified and ends debrided. Bilateral intravesicular neoureterocystostomy with mucosal apposition¹⁹ was performed with three 6-0 prolene sutures on each side. Cystotomy closure was routine. Amoxicillin clavulanate was continued for four days until receipt of negative urine culture results and epidural ropivacaine was continued for two days followed by intravenous buprenorphine (Vetergesic, Ceva) until discharge. The abdominal drain was

1 maintained for four days. Intravenous Hartmanns' solution was continued for four
2 days as required to maintain blood pressure and to match urine output.

3
4
5 Urination was seen within three hours after neoureterocystostomy and blood
6 analysis was improved by 12 hours (Table 1). Appetite returned by 24 hours. On
7 the third post-operative day biochemistry revealed normal urea 9.3mmol/l (6.1-
8 12mmol/l) and creatinine 82 µmol/l (74.5-185.3 µmol/l). The cat was discharged
9 on the seventh postoperative day.

10 **OUTCOME AND FOLLOW-UP**

11 Six weeks after neoureterocystostomy, fluoroscopy (Axiom Iconos R200, Siemens)
12 with iohexol injection into the SUB ports revealed patent bilateral SUBs and patent
13 normal ureters bilaterally (Figure 3; Video 3). Three months after discharge acute
14 onset vomiting, lethargy and anorexia were noted. Abdominal ultrasound,
15 abdominocentesis and fluoroscopy with iohexol injection into SUB ports revealed
16 uroabdomen secondary to displacement of left cystostomy catheter from the bladder
17 into the peritoneal cavity (Figure 4; Video 4). Both ureters were patent and
18 demonstrating normal peristalsis. Both SUBs were removed at laparotomy. 4-0
19 polydioxanone (PDS II, Ethicon) sutures were used to close the renal capsule and
20 the bladder at catheter stoma sites. Urine infection with *Enterococcus faecalis* was
21 treated with a two-week course of oral amoxicillin clavulanate (Noroclav, Norbrook),
22 according to the results of culture and sensitivity testing. Urine culture one week
23 after this course of antibiotics confirmed resolution of infection.
24
25 Twenty-four months after the final surgery, the cat was reported to be clinically
26 well, living a normal happy life.

27 **DISCUSSION**

28 This study reports, for the first time, the use of bilateral SUBs as an emergency
29 temporary technique, to improve metabolic status in a cat with bilateral ureteral
30 ligation, prior to definitive repair by bilateral neoureterocystostomy.
31
32 The use of unilateral SUB in a 17-week-old kitten, for management of unilateral
33 ureteral ligation during ovariohysterectomy, has been reported previously, but as a
34 definitive treatment, rather than as a bridge to primary ureteral repair¹⁰. Whilst the
35 17-week-old kitten in that report was well 16 months post-surgery, longer term
36 complications in cats with SUBs have been reported including device occlusion due
37 to mineralisation and chronic bacteriuria^{16, 20, 21, 22}. A procedure to avoid long-term
38 SUBs in very young patients is therefore expedient.
39
40 Bilateral temporary nephrostomy catheters have been used successfully as a bridge
41 to definitive ureteral repair in a cat with bilateral ureteral transection during
42 ovariohysterectomy¹¹. A potential advantage of a nephrostomy catheter over a
43
44
45
46
47
48
49
50
51
52
53
54
55
56
57
58
59
60

1 SUB would be a simple percutaneous approach avoiding open laparotomy in critical
2 patients. However open laparotomy is recommended for nephrostomy tube
3 placement in cats to pexy the mobile feline kidney to the body wall ²³. Nephrostomy
4 catheters in cats are reported to have frequent short term complications including
5 migration out of the kidney and urine leak, which could compromise their successful
6 use as a bridging procedure for ureteral ligation ^{11, 23}.

7
8
9
10
11 Placement of SUBs in the reported cat limited two important potential short-term
12 post-operative complications of neoureterocystostomy, namely temporary ureteral
13 obstruction at, and urine leak from, the site of neoureterocystostomy ²⁴. SUB
14 removal was performed following displacement of the left cystostomy catheter from
15 the bladder. SUB removal was not performed prior to this, as SUB removal has not
16 been fully evaluated and therefore the risk of complications with this procedure was
17 not justified in a clinically well cat ¹⁶. SUB removal was uncomplicated in our case,
18 with the risk of potential urine leakage monitored by placement of an abdominal
19 drain.

20
21
22
23
24
25
26 The success of this case was in part due to early diagnosis and treatment of ureteral
27 ligation. The presenting clinical picture is identical to previous reports of complete
28 bilateral ureteric ligation including depression, lethargy, inappetence, nausea, pain,
29 azotaemia, hyperkalaemia and metabolic acidosis ^{11, 12}. Diagnosis was based on a
30 strong clinical suspicion resulting from complicated ovariohysterectomy in which
31 visualisation of the surgical field was obscured by bleeding and confirmed by
32 antegrade pyelography. Antegrade pyelography was achieved by direct injection of
33 contrast into the renal pelvises. This method of contrast administration was
34 preferred to intravenous injection, as it reduced the risk of iohexol-induced acute
35 kidney injury and successful opacification of the renal pelvises and ureters was
36 independent of renal function ¹⁵. Abdominal ultrasound findings of severe
37 hydronephrosis and proximal hydroureter have been the principle reported method
38 for confirming a clinical suspicion of iatrogenic ureteral ligation in dogs and cats to
39 date ¹. The main differentials for the presenting clinical picture were acute kidney
40 injury secondary to toxins (non-steroidal anti-inflammatory drugs, ethylene glycol,
41 toxic plants), ureteroliths, trauma, infection and neoplasia ¹⁷.

42
43
44
45
46
47
48
49
50
51
52
53 Peri-operative intravenous amoxicillin clavulanate was given according to standard
54 hospital protocol for all soft tissue surgeries with the potential to last more than 90
55 minutes. The decision to continue antibiotics post-operatively, pending urine culture
56 results, was made due to the perceived increased risk of surgical site infection due
57 to complicated ovariohysterectomy, multiple surgeries and a critically ill patient ²⁵.

1
2
3
4
5
6
7
8
9
10
11
12
13
14
15
16
17
18
19
20
21
22
23
24
25
26
27
28
29
30
31
32
33
34
35
36
37
38
39
40
41
42
43
44
45
46
47
48
49
50
51
52
53
54
55
56
57
58
59
60

Despite early diagnosis, a period of medical management to reduce hyperkalaemia and acidosis was appropriate due to concerns that the cat would not survive an anaesthetic. However equally important was the recognition that complete stabilisation required renal decompression, which was clear from the response to bilateral SUB placement. Nevertheless as definitive ureteral repair was the ultimate goal, this was performed as soon as improvement in blood analysis was seen and a surgical team with magnification was available. In this case report, emergency bilateral SUB placement was elected as the initial surgery, as the emergency surgeon judged that SUB placement would be faster than ureteral re-implantation in the unstable patient and they were also unfamiliar with operating with magnification.

LEARNING POINTS/TAKE HOME MESSAGES

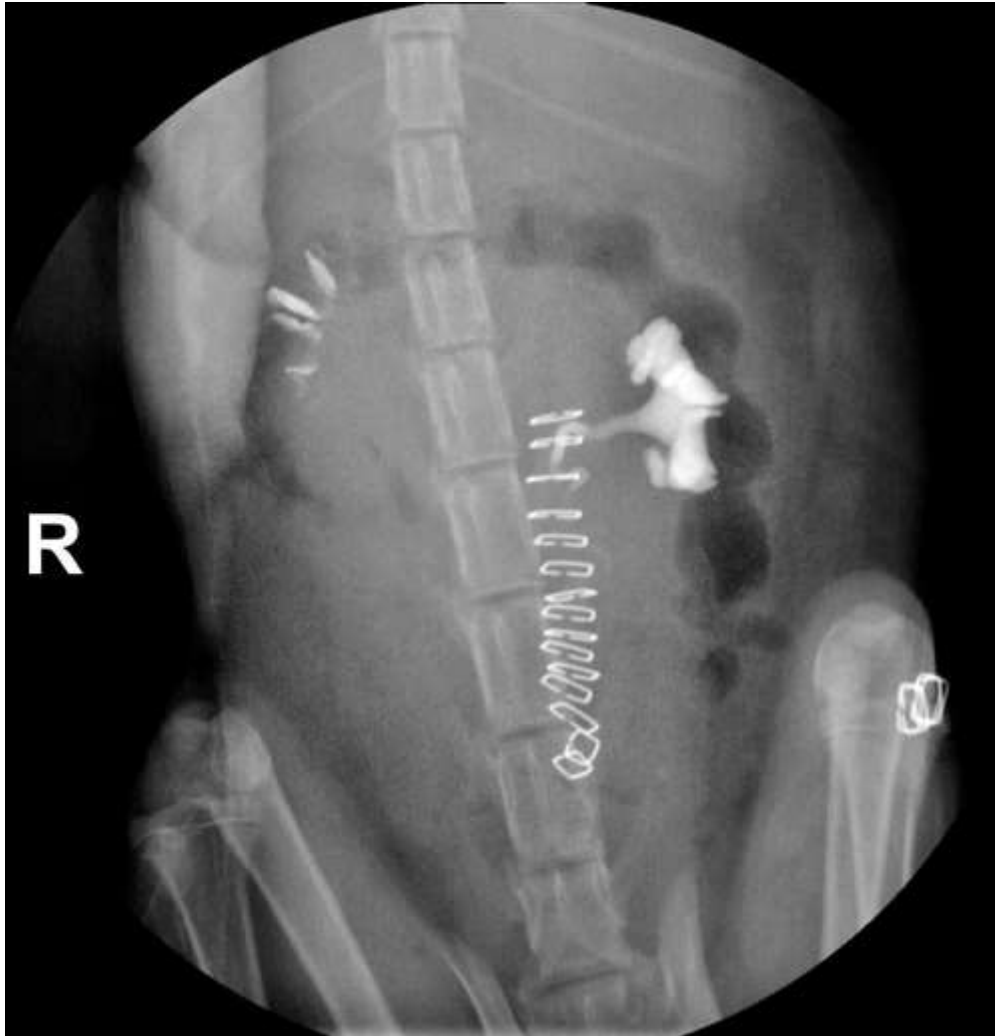- Bilateral ureteral ligation should be suspected in animals presenting with clinical and biochemical signs of acute kidney injury in the days after ovariohysterectomy, especially if complications such as bleeding compromised visualisation of the surgical site.
- A clinical suspicion of bilateral ureteral ligation can be confirmed by ultrasound and antegrade pyelography, which reveal bilateral hydronephrosis and failure of complete opacification of the ureters.
- Successful treatment of bilateral ureteral ligation requires early intervention and intensive management with both medical and surgical approaches.
- In cats with bilateral ureteral injury, subcutaneous ureteral bypass systems can be used as an emergency temporary measure to relieve hydronephrosis, to limit long-term renal dysfunction and to act as a bridge to definitive ureteral repair, which requires magnification and specialist surgeons.

REFERENCES

1. Adin CA. Complications of ovariohysterectomy and orchietomy in companion animals. *Vet Clin North Am Small Anim Pract.* 2011;41(5):1023-39.
2. Ito K, Chen J, El Char M, Stern JM, Seshan SV, Khodadadian JJ, et al. Renal damage progresses despite improvement of renal function after relief of unilateral ureteral obstruction in adult rats. *Am J Physiol Renal Physiol.* 2004;287(6):F1283-93.
3. Lucarelli G, Ditunno P, Bettocchi C, Grandaliano G, Gesualdo L, Selvaggi FP, et al. Delayed relief of ureteral obstruction is implicated in the long-term

- 1 development of renal damage and arterial hypertension in patients with unilateral
2 ureteral injury. *J Urol.* 2013;189(3):960-5.
- 3
- 4 4. Dickerson VM, Rissi DR, Brown CA, Brown SA, Schmiedt CW. Assessment of
5 Acute Kidney Injury and Renal Fibrosis after Renal Ischemia Protocols in Cats. *Comp*
6 *Med.* 2017;67(1):56-66.
- 7
- 8 5. Borthwick R. Unilateral hydronephrosis in a spayed bitch. *Vet Rec.*
9 1972;90(9):244-5.
- 10
- 11 6. Turner T. An unusual case of hydronephrosis in a spayed Alsatian bitch. *Vet*
12 *Rec.* 1972;91(24):588-90.
- 13
- 14 7. Tidwell AS, Ullman SL, Schelling SH. Urinoma (para-ureteral pseudocyst) in a
15 dog. *Veterinary Radiology.* 1990;31(4):203-6.
- 16
- 17 8. Kyles AE, Douglass JP, Rottman JB. Pyelonephritis following inadvertent
18 excision of the ureter during ovariohysterectomy in a bitch. *Vet Rec.*
19 1996;139(19):471-2.
- 20
- 21 9. Mehl ML, Kyles AE. Ureteroureterostomy after proximal ureteric injury during
22 an ovariohysterectomy in a dog. *Vet Rec.* 2003;153(15):469-70.
- 23
- 24 10. Johnson CM, Culp WT, Palm CA, Zacuto AC. Subcutaneous ureteral bypass
25 device for treatment of iatrogenic ureteral ligation in a kitten. *J Am Vet Med Assoc.*
26 2015;247(8):924-31.
- 27
- 28 11. Nwadike BS, Wilson LP, Stone EA. Use of bilateral temporary nephrostomy
29 catheters for emergency treatment of bilateral ureter transection in a cat. *J Am Vet*
30 *Med Assoc.* 2000;217(12):1862-5.
- 31
- 32 12. Kang B-T, Park C, Jung D-I, Yoo J-H, Kim J-W, Gu S-H, et al. Iatrogenic
33 hydroureter and hydronephrosis following hysterotomy with ovariohysterectomy in a
34 pregnant dog. *Korean J Vet Res.* 2007;47(2):213-17.
- 35
- 36 13. Ruiz de Gopegui R, Espada Y, Majo N. Bilateral hydroureter and
37 hydronephrosis in a nine-year-old female German shepherd dog. *J Small Anim Pract.*
38 1999;40(5):224-6.
- 39
- 40 14. Aronson LR, Cleroux A, Wormser C. Use of a modified Boari flap for the
41 treatment of a proximal ureteral obstruction in a cat. *Vet Surg.* 2018;47(4):578-85.
- 42
- 43 15. Adin CA, Herrgesell EJ, Nyland TG, Hughes JM, Gregory CR, Kyles AE, et al.
44 Antegrade pyelography for suspected ureteral obstruction in cats: 11 cases (1995-
45 2001). *J Am Vet Med Assoc.* 2003;222(11):1576-81.
- 46
- 47 16. Berent AC, Weisse CW, Bagley DH, Lamb K. Use of a subcutaneous ureteral
48 bypass device for treatment of benign ureteral obstruction in cats: 174 ureters in
49 134 cats (2009-2015). *J Am Vet Med Assoc.* 2018;253(10):1309-27.
- 50
- 51
- 52
- 53
- 54
- 55
- 56
- 57
- 58
- 59
- 60

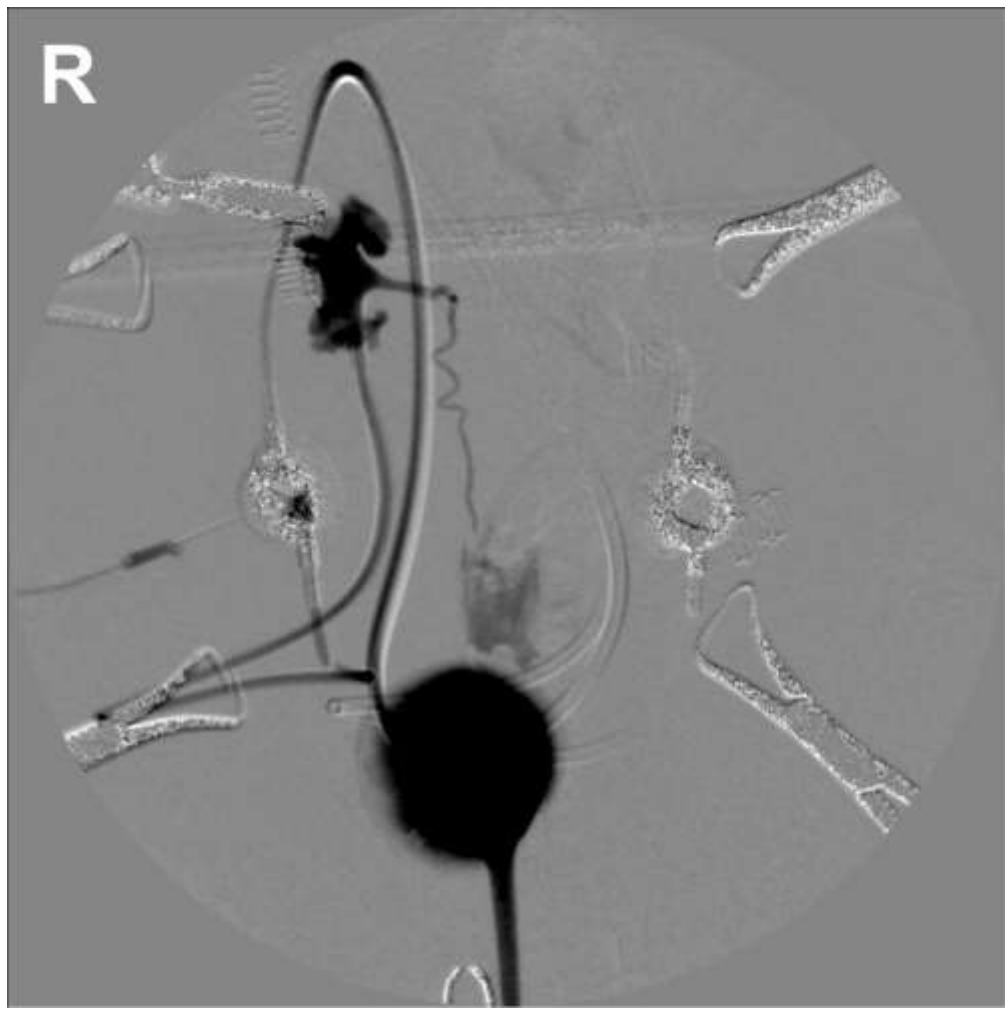17. Cole L, Jepson R, Humm K. Systemic hypertension in cats with acute kidney injury. *J Small Anim Pract.* 2017;58(10):577-81.
18. Kulendra E, Kulendra N, Halfacree Z. Management of bilateral ureteral trauma using ureteral stents and subsequent subcutaneous ureteral bypass devices in a cat. *J Feline Med Surg.* 2014;16(6):536-40.
19. Gregory CR, Lirtzman RA, Kochin EJ, Rooks RL, Kobayashi DL, Seshadri R, et al. A mucosal apposition technique for ureteroneocystostomy after renal transplantation in cats. *Vet Surg.* 1996;25(1):13-7.
20. Berent AC. Interventional urology: endourology in small animal veterinary medicine. *Vet Clin North Am Small Anim Pract.* 2015;45(4):825-55.
21. Livet V, Pillard P, Goy-Thollot I, Maleca D, Cabon Q, Remy D, et al. Placement of subcutaneous ureteral bypasses without fluoroscopic guidance in cats with ureteral obstruction: 19 cases (2014-2016). *J Feline Med Surg.* 2017;19(10):1030-9.
22. Horowitz C, Berent A, Weisse C, Langston C, Bagley D. Predictors of outcome for cats with ureteral obstructions after interventional management using ureteral stents or a subcutaneous ureteral bypass device. *J Feline Med Surg.* 2013;15(12):1052-62.
23. Berent AC, Weisse CW, Todd KL, Bagley DH. Use of locking-loop pigtail nephrostomy catheters in dogs and cats: 20 cases (2004-2009). *J Am Vet Med Assoc.* 2012;241(3):348-57.
24. Mehl ML, Kyles AE, Reimer SB, Flynn AK, Pollard RE, Nyland T, et al. Evaluation of the effects of ischemic injury and ureteral obstruction on delayed graft function in cats after renal autotransplantation. *Vet Surg.* 2006;35(4):341-6.
25. Verwilghen D, Singh A. Fighting surgical site infections in small animals: are we getting anywhere? *Vet Clin North Am Small Anim Pract.* 2015;45(2):243-76.



Bilateral pyelography demonstrating bilateral hydronephrosis, failure of opacification of entire right ureter and distal left ureter. Skin staples are present along the ventral midline and left flank from previous ovariohysterectomy procedure.

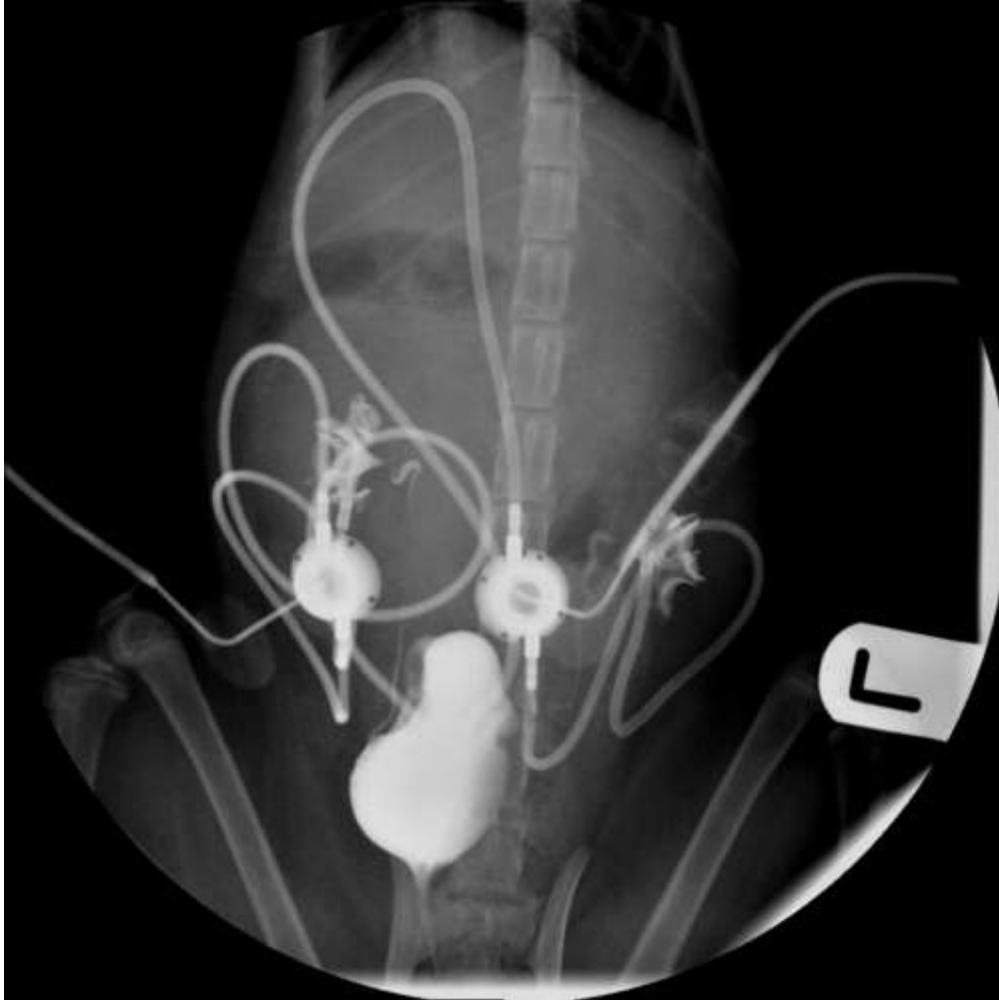411x425mm (72 x 72 DPI)

1
2
3
4
5
6
7
8
9
10
11
12
13
14
15
16
17
18
19
20
21
22
23
24
25
26
27
28
29
30
31
32
33
34
35
36
37
38
39
40
41
42
43
44
45
46
47
48
49
50
51
52
53
54
55
56
57
58
59
60



Fluoroscopy with negative subtraction and iohexol injection into right SUB port reveals right hydronephrosis and contrast leak from the mid right ureter.

393x393mm (72 x 72 DPI)

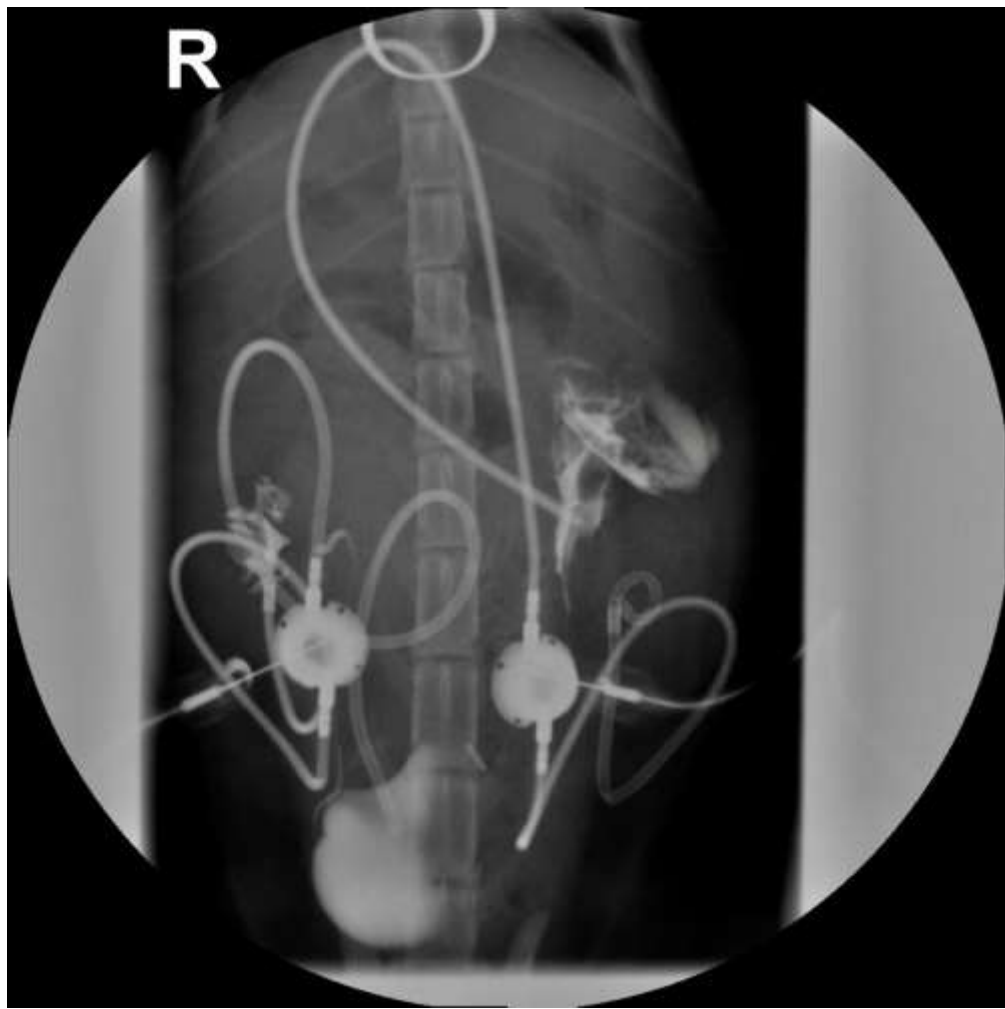


Fluoroscopy with iohexol injection into SUB ports reveals patent bilateral SUBs and normal ureters.

436x436mm (72 x 72 DPI)

1
2
3
4
5
6
7
8
9
10
11
12
13
14
15
16
17
18
19
20
21
22
23
24
25
26
27
28
29
30
31
32
33
34
35
36
37
38
39
40
41
42
43
44
45
46
47
48
49
50
51
52
53
54
55
56
57
58
59
60

1
2
3
4
5
6
7
8
9
10
11
12
13
14
15
16
17
18
19
20
21
22
23
24
25
26
27
28
29
30
31
32
33
34
35
36
37
38
39
40
41
42
43
44
45
46
47
48
49
50
51
52
53
54
55
56
57
58
59
60



Fluoroscopy with iohexol injection into SUB ports reveals patent right SUB and normal right ureter, but displacement of left cystostomy catheter from the bladder into the peritoneal space.

436x436mm (72 x 72 DPI)