



Editorial

Monkeypox – Enhancing public health preparedness for an emerging lethal human zoonotic epidemic threat in the wake of the smallpox post-eradication era



ARTICLE INFO

ABSTRACT

The identification of monkeypox in 3 separate patients in the United Kingdom in September raised media and political attention on an emerging public health threat. Nigeria, whose last confirmed case of monkeypox was in 1978, is currently experiencing an unusually large and outbreak of human monkeypox cases, a 'One Human-Environmental-Animal Health' approach is being effectively used to define and tackle the outbreak. As of 13th October 2018, there have been one hundred and sixteen confirmed cases the majority of whom are under 40 years. Over the past 20 years ten Central and West African countries have reported monkeypox cases which have risen exponentially. We review the history and evolution of monkeypox outbreaks in Africa and USA, the changing clinical presentations, and discuss possible factors underlying the increasing numbers being detected including the cessation of smallpox vaccination programs. Major knowledge gaps remain on the epidemiology, host reservoir, and emergence, transmission, pathogenesis and prevention of monkeypox.

© 2018 The Author(s). Published by Elsevier Ltd on behalf of International Society for Infectious Diseases. This is an open access article under the CC BY-NC-ND license (<http://creativecommons.org/licenses/by-nc-nd/4.0/>).

Introduction

The repeated outbreaks of zoonotic infectious diseases with epidemic potential in Central and West Africa, such as Ebola, Rift valley fever, Chikungunya and Dengue, continue to pose major public health threats to regional, continental and global health security (WHO, 2018a,b). Whilst lessons are being learnt from each outbreak (Zumla et al., 2017), and the 'One Human-Environmental-Animal Health' approach is gaining momentum (Eteng et al., 2018), much more remains to be done to achieve a substantial change of the status quo (Zumla et al., 2016). Critical to achieving this will be to effectively take forward and consolidate new African-led initiatives (Nkengasong et al., 2017; Nkengasong and Onyebujoh, 2018) that will reinforce integration of contextual knowledge of drivers and risks, and better enable Africa's preparedness to tackle and prevent emerging and re-emerging infectious diseases threats.

Monkeypox in the United Kingdom

Monkeypox has recently focused global media, political and scientific attention after the identification in the United Kingdom (UK) in September 2018 of 3 separate patients diagnosed with monkeypox (PHE, 2018). The first 2 had a recent travel history to Nigeria where there is an ongoing outbreak of the disease (Vaughan et al., 2018). Both cases were symptomatic during their return flight to the UK. A third case of monkeypox in the United Kingdom

occurred in a healthcare worker who cared for one of the two first cases. The healthcare worker was infected well before monkeypox was suspected and special infection control precautions were put in place. Secondary and tertiary human-to-human transmission of monkeypox has been well documented (Jezek et al., 1986; Nolen et al., 2016; Kalthan et al., 2018). Since these three cases of human monkeypox were the first ever reported from the European Union (EU) and the disease has similar clinical features with smallpox which had a devastating impact globally, media hype and enhanced political, and scientific attention ensued. Whilst the clinical manifestations of monkeypox are milder than smallpox, the disease can be fatal with case fatality rate between 1% and 10% being reported (Jezek et al., 1988a,b; Hutin et al., 2001; Di Giulio and Eckburg, 2004; Jezek et al., 1987a,b).

Monkeypox in Central and West Africa

Nigeria, whose last confirmed case of monkeypox was in 1978 (Gromyko and Daramola, 1979), is currently experiencing an unusually large and lethal outbreak (WHO, 2017; CDC, 2017; Yinka-Ogunleye et al., 2018). On September 22, 2017, the Nigeria Centre for Disease Control (NCDC) commenced an outbreak investigation following the identification of an 11-year old child with suspected monkeypox (Eteng et al., 2018). Epidemic preparedness requires close collaboration between human and animal health sectors to define the outbreak and effectively

respond in order to prevent regional and global spread. The Nigeria CDC was prepared, activating a multiagency interdisciplinary emergency operations center (EOC) on October 9th, 2017, which took forward a well implemented comprehensive incident action plan (NCDC, 2018). This included targeted epidemiological and research investigations at high-risk areas at the Human-Environmental-Animal interface, enhanced laboratory diagnostic and rapid sequencing capacities, assessment of risk factors and modes of transmission. (Yinka-Ogunleye et al., 2018; Faye et al., 2018). Available data suggest that human cases are not epidemiologically linked in the current outbreak, and that it is either a multisource outbreak with limited human to human transmission or an outbreak that has arisen from increased human contact with previously undetected endemically infected humans (Nigeria CDC, 2018; Durski et al., 2018a; Faye et al., 2018). The exact zoonotic origin and the specific role(s) of environmental and ecological factors in the Nigeria outbreak are not yet known.

New cases of monkeypox continue to be detected in Nigeria. As of 13th October 2018, there have been one hundred and sixteen confirmed cases (with 8 deaths = 6% mortality), and 280 additional suspected cases from across 16 Nigerian States (Nigeria CDC, 2018) affecting children and adults of all ages (Figure 1). The majority of confirmed monkeypox cases are under 40 years with a median age of 31 years. Notably, these people were born after global vaccination programs for smallpox were discontinued in 1978. Studies in monkeys have shown that immunization with smallpox vaccine induces cross-protection against monkeypox (McConnell et al., 1968). The question arises – did the mass smallpox vaccination program help prevent the spread of human monkeypox? There have been several suggestions (Durski et al., 2018a; Rimoin et al., 2010; Reynolds and Damon, 2012) that increasing number of monkeypox cases in Central and West Africa is probably a consequence of the cessation of smallpox vaccination in the early 1980s, following the eradication of smallpox. The apparent lack of cross-protection against monkeypox among the non-vaccinated younger age groups and the waning smallpox vaccine-induced population immunity in the

vaccinated groups, may contribute to the increased susceptibility to monkeypox infection. This creates an ecological niche where the monkey pox virus can expand in humans outside its natural reservoir.

Of note is that the number of human monkeypox cases being reported have risen exponentially over the past 20 years, more than the total number of cases over the previous 45 years since its first discovery (WHO, 2018a,b; Sklenovska and van Ranst, 2018; Durski et al., 2018a; Yinka-Ogunleye et al., 2018; Rimoin et al., 2010). To date human cases of monkeypox have been reported from ten African countries – Democratic Republic of the Congo, Republic of the Congo, Cameroon, Central African Republic, Nigeria, Ivory Coast, Liberia, Sierra Leone, Gabon and South Sudan (WHO, 2018a,b). Whilst the cessation of smallpox vaccination might be an important risk factor, there may be other factors which could explain the increase (Nolen et al., 2015; Sklenovská and Van Ranst, 2017) such as: (a) higher frequency of contact with animal host reservoirs by children and young adults, (b) deforestation leading to increased exposure of humans with displaced animals, (c) Wars, conflicts and poverty leading to population movement into forests, (d) reliance on rodents for food, (e) increased population density, and (f) Improved surveillance and diagnostic capability, although the latter was probably not the case due to reduced resources. Further multidisciplinary, regional collaborative research, including carefully designed case-control and cohort studies are required to fill the major knowledge gaps in the epidemiology, host reservoir, transmission, pathogenesis surveillance and prevention, as well as to explore potential prevention, infection control and treatment interventions.

The World Health Organisation (WHO) (WHO, 2018a,b) currently considers monkeypox to be “a rare viral zoonotic disease that occurs primarily in remote parts of central and Africa, near tropical rainforests”. This WHO statement may no longer be valid, and requires further discussion, review of evidence and debate. There is thus an urgent need for the conduct of priority research and surveillance through a combined ‘ONE-Human-Environmental-Animal-Health’ effort across Central and West Africa to increase the evidence base

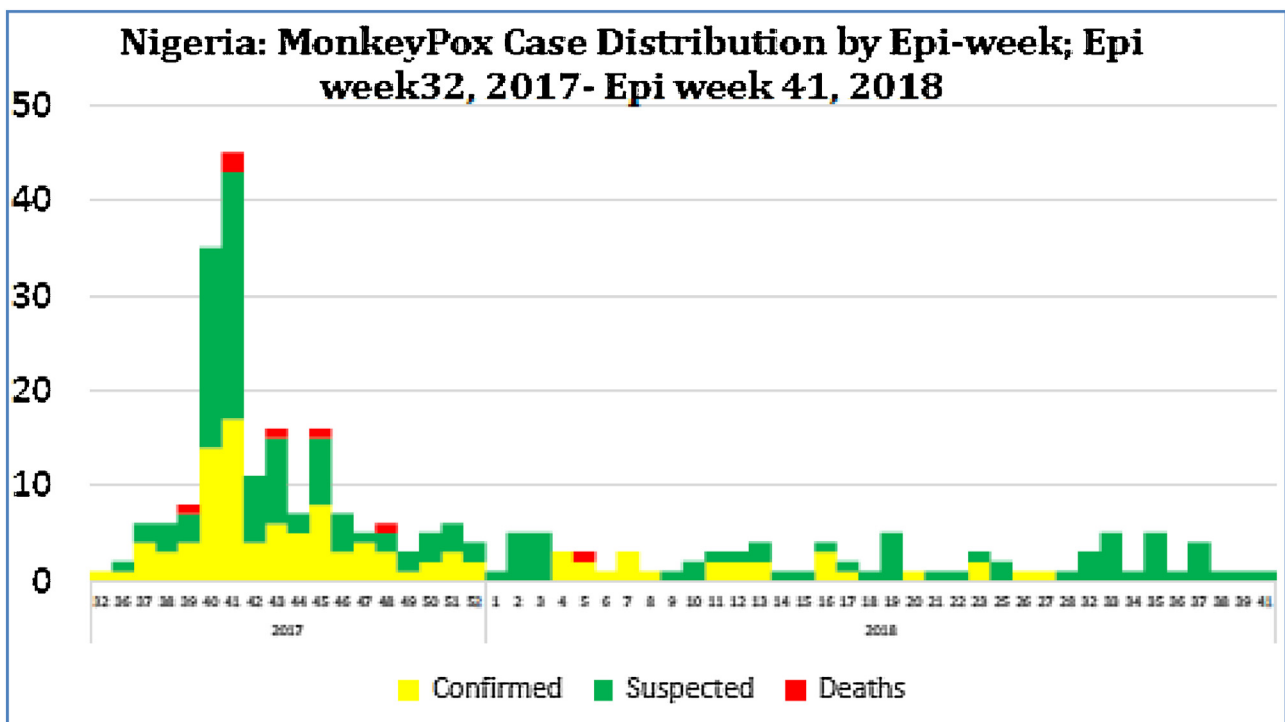


Figure 1. (Source: 'Situation Report- Nigeria CDC. www.ncdc.gov.ng).

(Zumla et al., 2017; Doshi et al., 2018; Bass et al., 2013). The continuing spread of monkeypox across a wide geographic area of Central and West Africa, and the real potential for further spread regionally and internationally is of major concern and requires coordinated review (Durski et al., 2018a; Sklenovska and van Ranst, 2018). The ecological, zoonotic, epidemiological, clinical and public health aspects of monkeypox remain inadequately characterized (WHO, 2018a,b; Heymann et al., 1998; Sklenovska and van Ranst, 2018; Rimoin et al., 2007, 2010; Hoff et al., 2017; Learned et al., 2005; Durski et al., 2018a; Yinka-Ogunleye et al., 2018). Data from reports and case studies of sporadic outbreaks in West and Central Africa over the past 50 years provide basic understanding, although the available literature is limited in its scope and the outbreak reports are incomparable. It is an opportune time to reflect on the discovery and historical evolution of monkeypox in Central and West Africa and view this in light of the current global attention on emerging infections.

First discovery and animal host reservoir

The monkeypox virus was first discovered in 60 years ago (von Magnus et al., 1959) and continues to remain on the radar of WHO since then (Heymann et al., 1998; Breman et al., 1980; WHO, 1984; WHO, 2018a,b). This zoonotic infection remains endemic to Central and West Africa in animal(s) reservoir(s), with increasing numbers of human cases and outbreaks being reported (Sklenovska and van Ranst, 2018; , 2007; , 2010; Hoff et al., 2017; Learned et al., 2005; Durski et al., 2018a; Yinka-Ogunleye et al., 2018). Monkeypox is caused by a double stranded DNA virus which belongs to the Orthopoxvirus genus of the family Poxviridae family (WHO, 2018a,b; CDC, 2018; Shchelkunov et al., 2001). The monkeypox virus was first detected in the 1958 in an outbreak of a vesicular diseases in captive monkeys brought to Copenhagen, Denmark from Africa for research purposes, hence the name monkeypox (von Magnus et al., 1959). The term 'monkeypox' may be inappropriate since the virus has been found in rodents and squirrels and the specific host reservoir has not yet been identified (Doty et al., 2017). The extent of the host animal reservoir, the natural history and pathogenesis of monkeypox in both animal and humans remains unknown and requires definition through case-control studies. In August 1970 the first human case of monkeypox was identified in a 9-year-old child with smallpox-like vesicular skin lesions in the village of Bukenda in the Equatorial region of Zaire (now Democratic Republic of Congo – DRC) (Marennikova et al., 1972). This patient was found during a period of intensified surveillance for smallpox cases, 9 months after the elimination of smallpox in DRC was certified by WHO. Retrospective studies indicated that similar cases had occurred between 1970–1971 in the Ivory Coast, Liberia, Nigeria, and Sierra Leone (Fine et al., 1988; Heymann et al., 1998; Breman et al., 1980; WHO, 1980). Subsequent increased surveillance led to a steady increase in the number of human monkeypox cases being identified, and each human case was investigated using standardized case investigation forms. Cases continued to be detected as isolated cases, in small clusters, or during large outbreaks in the community and in households (Nolen et al., 2016). An exponential rise in the number of cases were reported from the DRC (Learned et al., 2005; Reynolds et al., 2013; Nolen et al., 2016) and from across Central and West Africa has occurred over the past two decades (WHO, 2018a,b; Khodakevich et al., 1985; Sklenovska and van Ranst, 2018; Rimoin et al., 2007, 2010; Learned et al., 2005; Kantele et al., 2016; Hoff et al., 2017; Durski et al., 2018a; Yinka-Ogunleye et al., 2018).

Monkeypox prevalence, changing clinical presentations and smallpox vaccination

In 1980, the Global Commission for the Certification of Smallpox Eradication (GCCSE) continued to designate monkeypox

as an important public health threat and recommended that the epidemiological, ecological and surveillance program on monkeypox be continued (WHO, 1980). In response, the WHO supported an active surveillance program for human monkeypox from 1981 to 1986. Other countries of Central and West Africa continued to report cases of monkeypox in humans and in wildlife (Doty et al., 2017; Hutin et al., 2001). At the end of the smallpox eradication campaign, the GCCSE stated that continued smallpox vaccination to prevent monkeypox was not justified based on the evidence available at that time.

The clinical presentation of monkeypox includes symptoms with skin and mucosal lesions which are difficult to distinguish from smallpox (Jezek et al., 1987a,b; Jezek et al., 1988a,b; Hutin et al., 2001; Di Giulio and Eckburg, 2004). As with smallpox, the prodromal period of monkeypox infection starts with fever, headache, back pain, myalgia and asthenia followed by eruption of skin and mucosal lesions starting with the face (within 1–3 days after development of fever). The lesions evolve from maculopapular to fluid filled vesicles to pustules followed by crusting within 10 days and complete disappearance of the crusts within 3 weeks (Nigeria CDC, 2018; Osadebe et al., 2017). Whilst immunosuppression may be a risk factor for severe disease, the effects of HIV co-infection remain to be determined. Lymphadenopathy is common and may be a clinical distinguishing feature from smallpox. Laboratory tests available for confirming a diagnosis of monkeypox include Polymerase chain reaction (PCR), antigen detection tests, Enzyme-linked immunosorbent assay (ELISA) and viral cell culture (PHE, 2018; CDC, 2018).

Based on clinical and epidemiological features, and linking genotypic studies of monkeypox virus isolates two distinct clades of virus have been characterized (Likos et al., 2005; Nakazawa et al., 2015): Congo Basin (CB) and West African (WA). The CB clade is associated with higher (approximately 10%) mortality and seems to transmit more frequently between humans with several human-to-human transmission cycles. The WA clade causes milder disease with lower mortality rates (Breman et al., 1980).

There are differences in skin and mucosal lesions in patients with previous smallpox vaccination as defined by presence of vaccination scar, compared to those patients who were not vaccinated (Jezek et al., 1987a,b; Huhn et al., 2005; Damon, 2011; Di Giulio and Eckburg, 2004; McCollum and Damon, 2014). In vaccinated individuals the skin rashes and vesicles appear less intense, milder and more pleomorphic, and fewer in comparison with those unvaccinated individuals. Smallpox vaccination appeared to provide 85% protection against monkeypox infection (Fine et al., 1988). The average annual primary attack rate was estimated at 1.7 per 10,000 in those unvaccinated, compared to a rate of 0.04 per 10,000 among those who were vaccinated (Rimoin et al., 2010). Whilst new vaccines are being developed for monkeypox, there is a need to conduct controlled clinical trials to evaluate the efficacy and impact of smallpox vaccines for prevention of monkeypox or modification of disease severity. Studies should focus on the cost benefit of population level vaccination and investigation of alternative vaccination strategies such as targeting vaccination to affected areas, contacts and healthcare workers, and wider geographical areas. Currently, the CDC recommends pre-exposure smallpox vaccination for field investigators, veterinarians, animal-control personnel, contacts of monkeypox patients, researchers and healthcare workers caring for patients and their contacts (CDC 2018).

Several reviews have summarised human monkeypox outbreaks over the past 38 years (Rimoin et al., 2010; Sklenovská and Van Ranst, 2018; Durski et al., 2017; Durski et al., 2018b). Population-based surveillance studies conducted in nine health zones in DRC identified 760 laboratory-confirmed human monkeypox cases with an annual cumulative incidence of 5.53 per 10,000 (2.18–14.42) (Rimoin et al., 2010). Factors associated

with increased risk of infection included: living in forested areas, male gender, age less than 15 years, and absence of prior smallpox vaccination. A 5.2-fold lower risk of monkeypox was seen in those who had received smallpox vaccination than unvaccinated persons (0.78 vs. 4.05 per 10,000). A 20-fold increase in human monkeypox incidence was observed compared to surveillance data from the same region from the 1980s. Between January 2001 and December 2004, the DRC Ministry of Health surveillance program (Rimoin et al., 2007) reported that 2,734 cases of suspected human monkeypox from 11 provinces which showed annual upward trends: 380 cases in 2001, 545 in 2002, 783 in 2003, and 1026 in 2004. The majority of cases (94%) occurred in children and young adults less than 25 years of age who had not received smallpox vaccination. Surveillance activities after 2005 were then interrupted by the civil war over 20 years. In the conflict zone of the Kivu region refugee displacements into forested areas increased in 2012 when the war accelerated. Monkeypox cases continue to be reported from the DRC (Hoff et al., 2017) including areas of conflict (McCullum et al., 2015), with human to human transmission occurring during outbreaks (Nolen et al., 2016).

Animal exports and outbreaks in the USA

Monkeypox remained an ignored global public health threat and only became the center of global attention when the first human monkeypox cases outside Africa were detected in the United States of America in 2003 (CDC, 2003a,b,c). Several people in the mid-west United States developed fever, rash, respiratory symptoms, and lymphadenopathy and outbreak investigations linked the monkeypox cases following exposure to pet prairie dogs (*Cynomys species*) (CDC, 2003a). Cases of monkeypox were reported from six states—Illinois, Indiana, Kansas, Missouri, Ohio, and Wisconsin – during the 2003 U.S. outbreak (CDC, 2003b). Molecular and epidemiological investigations found that a west African genetic group (clade) of monkeypox was imported from Ghana into the state of Texas, USA on April 9, 2003, through a shipment of nine different species of small mammals, including six genera of African rodents (CDC, 2003c). Evidence of monkeypox virus was cultured from 22 animals and monkeypox DNA was found in at least 33 (Hutson et al., 2007). These included rope squirrels (*Funisciurus sp.*), tree squirrels (*Heliosciurus sp.*), brush-tailed porcupines (*Atherurus sp.*), African giant pouched rats (*Cricetomys sp.*), dormice (*Graphiurus sp.*), and striped mice (*Lemniscomys sp.*). Some of the infected animals were housed near North American prairie dogs (*Cynomys sp.*) which were sold as pets. The prairie dogs harbored large amounts of monkeypox virus which was detected in lesions in the, tongue, skin, lung, and eyelid samples (Hutson et al., 2007). Genomic studies of monkeypox viruses isolated from a human, a prairie dog, a rope squirrel, a dormouse, and a giant pouched rat showed identical viral isolates.

Animal reservoirs

Indirect or direct contact with live or dead animals is assumed to be the driver of human monkeypox infections in humans (Durski et al., 2018a; Sklenovská and Van Ranst, 2018). Monkeypox primarily occurs in animals in the equatorial rain forests in West Africa and Central Africa (WHO, 2018a,b; CDC, 2018; Nigeria CDC, 2018; Khodakevich et al., 1986; Hutin et al., 2001). In 1985, the virus was isolated from a moribund rope squirrel (*Funisciurus anerythrus*) in Zaire (DRC) during an outbreak investigation (Khodakevich et al., 1986). Evidence of monkeypox infection has been found in a range of animal species: squirrels (rope and tree), rats, striped mice, dormice and monkeys (Khodakevich et al., 1986; Reynolds et al., 2010; Radonić et al., 2012; Radonić et al., 2014; Doty et al., 2017). The specific animal host reservoir of monkeypox, the

natural history of animal and human monkeypox infections remains unknown. Further studies are needed to understand the extent of animal host reservoir, how the virus maintained in nature, the natural history, the pathogen–host associations and the effect of climatic and ecological factors which affect shifts of monkeypox between geographical areas and to causing disease in humans (Thomassen et al., 2013).

Modes of transmission

The exact mode of transmission of the monkeypox virus to humans remains unknown. Primary animal to human infection is assumed to occur through direct or indirect contact with monkeypox infected animal bodily fluids through handling, bites or scratches, although the specific mechanism(s) remains to be defined. The virus is thought to enter the body through broken skin, the respiratory tract, or the mucous membranes (eyes, nose, or mouth). Secondary human-to-human, transmission is well documented (Jezek et al., 1988a,b, 1986; Hutin et al., 2001) and is thought to occur through large respiratory droplets or direct or indirect contact with body fluids, lesion material, and contaminated surfaces or other material such as clothing or linens. Prolonged contact places hospital staff and family members at greater risk of infection. Nosocomial transmission has been recorded (Learned et al., 2005). There is no evidence, to date, that person-to-person transmission alone can sustain monkeypox infections in the human population.

There have been few genomic studies on the origins of monkeypox outbreaks. Human-to-human transmission has been reported from primary human cases, secondary cases (Arita et al., 1985; Jezek et al., 1986) and serial transmission across four cases has been observed (Nolen et al., 2016). In the current monkeypox outbreak in Nigeria, genomic studies on monkeypox virus isolates from human cases (Faye et al., 2018) suggest that the index case was not imported into Nigeria. Current evidence suggests that the outbreak is caused by multiple source emergence into the human population, and not sustained by human to human transmission. The zoonotic source(s) of the outbreak are currently under investigation, and it is unclear what, if any, environmental or ecological changes might have facilitated its sudden reemergence in Nigeria. Clustering of cases has been identified within states, although no epidemiological linkages across states have yet been identified. Three family clusters have been identified and this suggests human-to-human transmission (Nigeria CDC, 2018; Faye et al., 2018). In one family the secondary attack rate was 71%. However, since most cases have no obvious epidemiologic linkage suggestive of person-to-person contact, the hypothesis of a multiple-source outbreak is reinforced, but this does not exclude emergence from contact with humans that are a part of previously unrecognized human endemic disease.

Addressing gaps in knowledge and strengthening public health preparedness

Most of the currently available data on monkeypox comes from individual case or outbreak reports, and from passive intermittent surveillance, all of which do not portray an accurate overall picture. The rapid response by the Nigerian CDC (Nigeria CDC, 2018) to the ongoing monkeypox outbreak is example of how a locally led integrated Human-Animal Disease Surveillance and Response system can be used effectively to define the outbreak, and points the way forward for other African countries. Nigeria's experience is important for regional training and help build networks to improve surveillance capacity, laboratory diagnostics, best public health and clinical practice, and regional capacities to launch locally led efficient responses. This would contribute to the need to build public health

and surveillance capacities across Africa to guide appropriate surveillance, data collection, prevention, preparedness and response activities to monkeypox and other emerging and re-emerging infections with epidemic potential. Advancing public health preparedness and aligning proactive surveillance activities to priority research will require a coordinated, locally-led, multidisciplinary efforts aligned closely with capacity development and training.

Conclusions

An approximately 20-fold increase in monkeypox incidence compared to the historic data upto 1986 has occurred in and West Africa (WHO, 2018a,b; Sklenovska and van Ranst, 2018; Durski et al., 2018a; Yinka-Ogunleye et al., 2018; Rimoin et al., 2010). Novel lethal zoonotic pathogens of humans with epidemic potential and high mortality rates have threatened global health security for centuries and continue to do so (Zumla et al., 2017). The ecological gap of the increasing number of humans with no immunity to poxvirus after the end of the smallpox vaccination program resulted in a susceptible population where secondary epidemiological cycles can occur. Whilst there is no evidence to date, that person-to-person transmission alone can sustain these zoonotic infections in the humans, the continuing outbreaks caused by lethal zoonotic pathogens such as Ebola Virus, the Middle East respiratory Syndrome coronavirus and monkeypox virus highlights the interconnectedness between Humans, Animals and the Environment. This emphasizes that a 'One-Human-Environmental-Animal Health' approach is required to reduce the risk of outbreaks and this challenge warrants priority political and funder attention (Zumla et al., 2016). Whilst the 'One Human-Environmental-Animal Health' approach is gaining traction, much more remains to be done to achieve a substantial change to the status quo (Zumla et al., 2017).

Acknowledgements

All authors are part of PANDORA-ID-NET Consortium. FN, MB, TmC, IH and AZ are members of the Central Africa Network on Tuberculosis, HIV/AIDS and Malaria (CANTAM2) consortium. AZ, FN, IH, TmC and SM are members of the East African East African Consortium for Clinical Research EACCR2, All three consortia are supported by the European and Developing Countries Clinical Trials Partnership (EDCTP). AZ is in receipt of an NIHR senior investigator fellowship.

Funding source

This publication is part of the PANDORA-ID-NET, CANTAM2 (RegNet2015-1045), EACCR2 (RegNet2015- 1104) and TESA2 (RegNet2015-1051) Networks of Excellence grants funded by the European and Developing Countries Clinical Trials Partnership (EDCTP2) programme which is supported under Horizon 2020, the European Union's Framework Programme for Research and Innovation'. The views and opinions of authors expressed herein do not necessarily state or reflect those of EDCTP.

Conflicts of interest

All authors have an interest in global public health and emerging and re-emerging infections.

All authors have no other conflict of interest to declare.

References

Arita I, Jezek Z, Khodakevich L, Ruti K. Human monkeypox: a newly emerged orthopoxvirus zoonosis in the tropical rain forests of Africa. *Am J Trop Med Hyg* 1985;34(July (4)):781–9.

- Bass J, Tack DM, McCollum AM, Kabamba J, Pakuta E, Malekani J, et al. Enhancing health care worker ability to detect and care for patients with monkeypox in the Democratic Republic of the Congo. *Int Health* 2013;5:237–43.
- Breman JG, Kalisa R, Steniowski MV, Zanotto E, Gromyko AI, Arita I. Human monkeypox, 1970–79. *Bull World Health Organ* 1980;58:165–82.
- CDC. Monkeypox. 2018 <https://www.cdc.gov/poxvirus/monkeypox/index.html>. [Accessed October 27th 2018].
- CDC, 2017: Emergence of monkeypox in West Africa and Central Africa, 1970–2017. Centers for Disease Control and Prevention (CDC). Update: multistate outbreak of monkeypox—Illinois, Indiana, Kansas, Missouri, Ohio, and Wisconsin, 2003. *MMWR Morb Mortal Wkly Rep* 2003a;52:642.
- CDC Update. Multistate outbreak of monkeypox—Illinois, Indiana, Kansas, Missouri, Ohio, and Wisconsin, 2003. *MMWR Morb Mortal Wkly Rep* 2003b;52:589–90.
- CDC. Monkeypox in the United States. 2003 Outbreak. 2003 <https://www.cdc.gov/poxvirus/monkeypox/outbreak.html>. [Accessed October 31st, 2018].
- Damon IK. Status of human monkeypox: clinical disease, epidemiology and research. *Vaccine* 2011;29(Suppl. 4):D54–9 DOI:PubMed.
- Di Giulio DB, Eckburg PB. Human monkeypox: an emerging zoonosis. *Lancet* 2004;4:15–25.
- Doshi RH, Guagliardo SAJ, Dzabatou-Babeaux A, Likouayoulou C, Ndakala N, Moses C, et al. Strengthening of surveillance during monkeypox outbreak, Republic of the Congo, 2017. *Emerg Infect Dis* 2018;24(June (6)):1158–60.
- Doty JB, Malekani JM, Kalemba LN, Stanley WT, Monroe BP, Nakazawa YU, et al. Assessing monkeypox virus prevalence in small mammals at the human-animal interface in the Democratic Republic of the Congo. *Viruses* 2017;9(October (10)), doi:<http://dx.doi.org/10.3390/v9100283> pii: E283.
- Durski KN, McCollum AM, Nakazawa Y, Petersen BW, Reynolds MG, et al. Emergence of monkeypox — West and Central Africa, 1970–2017. *MMWR Morb Mortal Wkly Rep* 2018a;67(March (10)):306–10.
- Durski Kara N, McCollum Andrea M, Nakazawa Yoshinori, Brett W, et al. Emergence of monkeypox — West and Central Africa, 1970–2017. *MMWR Morb Mortal Wkly Rep* 2018b;67(March (10)):306–10.
- Eteng WE, Mandra A, Doty J, Yinka-Ogunleye A, Aruna S, Reynolds MG, et al. Notes from the field: responding to an outbreak of monkeypox using the one health approach — Nigeria, 2017–2018. *MMWR Morb Mortal Wkly Rep* 2018;67(September (37)):1040–1.
- Faye O, Pratt CB, Faye M, Fall G, Chitty JA, Diagne MM, et al. Genomic characterisation of human monkeypox virus in Nigeria. *Lancet Infect Dis* 2018;18(March (3)):246, doi:[http://dx.doi.org/10.1016/S1473-3099\(18\)30043-4](http://dx.doi.org/10.1016/S1473-3099(18)30043-4).
- Fine PE, Jezek Z, Grab B, Dixon H. The transmission potential of monkeypox virus in human populations. *Int J Epidemiol* 1988;17:643–50.
- Gromyko AI, Daramola M. Results of an investigation of a case of monkeypox in Nigeria [French]. Geneva, Switzerland: World Health Organization; 1979 http://apps.who.int/iris/bitstream/handle/10665/68316/SME_79.3.pdf?sequence=1&isAllowed=y. [Accessed 31st October 2018].
- Heymann DL, Szczeniowski M, Esteves K. Reemergence of monkeypox in Africa: a review of the past six years. *Br Med Bull* 1998;54:693–702.
- Hoff NA, Doshi RH, Colwell B, Kebela-Illunga B, Mukadi P, Mossoko M, et al. Evolution of a Disease surveillance system: an increase in reporting of human monkeypox disease in the Democratic Republic of the Congo, 2001–2013. *Int J Trop Dis Health* 2017;25(2), doi:<http://dx.doi.org/10.9734/IJTIDH/2017/35885> pii: IJTIDH.35885.
- Huhn GD, Bauer AM, Yorita K, Graham MB, Sejvar J, Likos A, et al. Clinical characteristics of human monkeypox, and risk factors for severe disease. *Clin Infect Dis* 2005;41:1742–51 DOI:PubMed.
- Hutin YJ, Williams RJ, Malfait P, Pebody R, Loparev VN, Ropp SL, et al. Outbreak of human monkeypox, Democratic Republic of Congo, 1996 to 1997. *Emerg Infect Dis* 2001;7:434.
- Hutson CL, Lee KN, Abel J, Carroll DS, Montgomery JM, Olson VA, et al. Monkeypox zoonotic associations: insights from laboratory evaluation of animals associated with the multi-state US outbreak. *Am J Trop Med Hyg* 2007;76(April (4)):757–68.
- Jezek Z, Szczeniowski M, Paluku KM, Mutombo M. Human monkeypox: clinical features of 282 patients. *J Infect Dis* 1987a;156:293–8.
- Jezek Z, Grab B, Dixon H. Stochastic model for interhuman spread of monkeypox. *Am J Epidemiol* 1987b;126:1082–92.
- Jezek Z, Szczeniowski M, Paluku KM, Mutombo M, Grab B. Human monkeypox: confusion with chickenpox. *Acta Trop* 1988a;45:297–307.
- Jezek Z, Grab B, Szczeniowski MV, Paluku KM, Mutombo M. Human monkeypox: secondary attack rates. *Bull World Health Organ* 1988b;66:465–70.
- Jezek Z, Arita I, Mutombo M, Dunn C, Nakano JH, Szczeniowski M. Four generations of probable person-to-person transmission of human monkeypox. *Am J Epidemiol* 1986;123:1004–12.
- Kantele A, Chickering K, Vapalahti O, Rimoin AW. Emerging diseases—the monkeypox epidemic in the Democratic Republic of the Congo. *Clin Microbiol Infect* 2016;22(August (8)):658–9.
- Kalthan E, Tenguere J, Ndjapou SG, Koyazengbe TA, Mbomba J, Marada RM, et al. Investigation of an outbreak of monkeypox in an area occupied by armed groups, Central African Republic. *Med Mal Infect* 2018;48(June (4)):263–8.
- Khodakevich L, Widy-Wirski R, Arita I, Marennikova SS, Nakano J, Meunier D, et al. Monkey pox virus infection in humans in the Central African Republic. *Bull Soc Pathol Exot Filiales* 1985;78:311–20.
- Khodakevich L, Jezek Z, Kinzanzka K. Isolation of monkeypox virus from wild squirrel infected in nature. *Lancet* 1986;1:98–9.
- Likos AM, Sammons SA, Olson VA, France MA, Li Y, Olsen-Rasmussen MA, et al. A tale of two clades: monkeypox viruses. *J Gen Virol* 2005;86:2661–72.

- Learned LA, Reynolds MG, Wassa DW, Li Y, Olson VA, Kareem K, et al. Extended interhuman transmission of monkeypox in a hospital community in the Republic of the Congo, 2003. *Am J Trop Med Hyg* 2005;73:428–734.
- Marennikova SS, Seluhina EM, Mal'ceva NN, Cimiskjan KL, Macevic GR. Isolation and properties of the causal agent of a new variola-like disease (monkeypox) in man. *Bull World Health Organ* 1972;46:599–611.
- McConnell S, Hickman RL, Wooding Jr. WL, Huxsoll DL. Monkeypox: experimental infection in chimpanzee (*Pan satyrus*) and immunization with vaccinia virus. *Am J Vet Res* 1968;29:1675–80.
- McCollum AM, Nakazawa Y, Ndongala GM, Pukuta E, Karhemere S, Lushima RS, et al. Human monkeypox in the Kivus, a conflict region of the Democratic Republic of the Congo. *Am J Trop Med Hyg* 2015;93(October (4)):718–21.
- McCollum AM, Damon IK. Human monkeypox. *Clin Infect Dis* 2014;58:260–7.
- Nakazawa Y, Mauldin MR, Emerson GL, Reynolds MG, Lash RR, Gao J, et al. A phylogeographic investigation of African monkeypox. *Viruses* 2015;7(April (4)):2168–84.
- Nkengasong J, Djoudalbaye B, Maiyegun O. A new public health order for Africa's health security. *Lancet Glob Health* 2017;5(November (11)):e1064–5.
- Nkengasong JN, Onyebujoh P. Response to the Ebola virus disease outbreak in the Democratic Republic of the Congo. *Lancet* 2018;391(June (10138)):2395–8.
- Nolen LD, Osadebe L, Katomba J, Likofata J, Mukadi D, Monroe B, et al. Introduction of monkeypox into a community and household: risk factors and zoonotic reservoirs in the Democratic Republic of the Congo. *Am J Trop Med Hyg* 2015;93(August (2)):410–5.
- Nolen LD, Osadebe L, Katomba J, Likofata J, Mukadi D, Monroe B, et al. Extended human-to-human transmission during a monkeypox outbreak in the Democratic Republic of the Congo. *Emerg Infect Dis* 2016;22:1014–21.
- Nigeria CDC. An update of monkeypox outbreak in Nigeria. 2018 <https://ncdc.gov.ng/diseases/sitreps/?cat=8&name=An%20Update%20of%20Monkeypox%20Outbreak%20in%20Nigeria>. [Accessed November 1st 2018].
- NCDC. Monkeypox outbreak response – interim national guidelines – October 2017. 2018 https://ncdc.gov.ng/themes/common/docs/protocols/50_1508912430.pdf. [Accessed October 27th 2018].
- Osadebe L, Hughes CM, Shongo Lushima R, Kabamba J, Nguete B, Malekani J, et al. Enhancing case definitions for surveillance of human monkeypox in the Democratic Republic of Congo. *PLoS Negl Trop Dis* 2017;11:e0005857.
- Public Health England. Monkeypox – latest update. 2018 <https://www.gov.uk/government/news/monkeypox-case-in-england>. [Accessed October 29th 2018].
- Radonić A, Metzger S, Dabrowski PW, Couacy-Hymann E, Schuenadel L, et al. Fatal monkeypox in wild-living sooty mangabey, Côte d'Ivoire, 2012. *Emerg Infect Dis* 2014;20(June (6)):1009–11.
- Radonić A, Metzger S, Dabrowski PW, Couacy-Hymann E, Schuenadel L, Kurth A, Mätz-Rensing K, Boesch C, Leendertz FH, Nitsche A. Fatal monkeypox in wild-living sooty mangabey, Côte d'Ivoire. *Emerg Infect Dis* 2012;20(June (6)):1009–11. doi:<http://dx.doi.org/10.3201/eid2006.13-1329>.
- Reynolds MG, Carroll DS, Olson VA. A silent zootic of an orthopoxvirus in Ghana, West Africa: evidence for multi-species involvement in the absence of widespread human disease. *Am J Trop Med Hyg* 2010;82:746–54.
- Reynolds MG, Damon IK. Outbreaks of human monkeypox after cessation of smallpox vaccination. *Trends Microbiol* 2012;20:80–7.
- Reynolds MG, Emerson GL, Pukuta E, Karhemere S, Muyembe JJ, Bikindou A, et al. Detection of human monkeypox in the Republic of the Congo following intensive community education. *Am J Trop Med Hyg* 2013;88:982–5 DOI:PubMed.
- Rimoin AW, Kitalu N, Kebela-Ilunga B, Mukaba T, Wright LL, Formenty P, et al. Endemic human monkeypox, Democratic Republic of Congo, 2001–2004. *Emerg Infect Dis* 2007;13(June (6)):934–7.
- Rimoin AW, Mulembakani PM, Johnston SC, Lloyd Smith JO, Kitalu NK, Kinkela TL, et al. Major increase in human monkeypox incidence 30 years after smallpox vaccination campaigns cease in the Democratic Republic of Congo. *Proc Natl Acad Sci U S A* 2010;107:16262–7.
- Shchelkunov SN, Totmenin AV, Babkin IV, et al. Human monkeypox and smallpox viruses: genomic comparison. *FEBS Lett* 2001;509:66–70.
- Sklenovská N, Van Ranst M. Emergence of monkeypox as the most important orthopoxvirus infection in humans. *Front Public Health* 2018;4(September (6)) 241. doi:<http://dx.doi.org/10.3389/fpubh.2018.00241> eCollection 2018.
- Thomassen HA, Fuller T, Asefi-Najafabady S, Shiplacoff JA, Mulembakani PM, Blumberg S, et al. Pathogen-host associations and predicted range shifts of human monkeypox in response to climate change in central Africa. *PLoS One* 2013;8(July (7))e66071.
- Vaughan A, Aarons E, Astbury J, Balasegaram S, Beadsworth M, Beck CR, et al. Two cases of monkeypox imported to the United Kingdom, September 2018. *Euro Surveill* 2018;23(September (38)), doi:<http://dx.doi.org/10.2807/1560-7917>.
- von Magnus P, Anderson EK, Petersen KB, Birch-Anderson A. A pox-like disease in cynomolgus monkeys. *Acta Pathol Microbiol Scand* 1959;46:156–76.
- WHO. The global eradication of smallpox: final report of the Global Commission for the Certification of Smallpox Eradication. Geneva: World Health Organization, 1980; 1980.
- WHO. Monkeypox. Nigeria. 2017 <https://www.who.int/csr/don/21-december-2017-monkeypox-nigeria/en/>. [Accessed 28th October, 2018].
- WHO. Emergencies. Disease outbreaks. 2018 <http://www.who.int/emergencies/diseases/en/>. [Accessed October 28th 2018].
- WHO. Human monkeypox (MPX). 2018 <http://www.who.int/emergencies/diseases/monkeypox/en/>. [Accessed 1st November 2018].
- WHO. The current status of human monkeypox: Memorandum from a WHO Meeting. *Bull World Health Organ* 1984;62(5):703–13.
- Yinka-Ogunleye A, Aruna O, Ogoina D, Aworabhi N, Eteng W, Badaru S, et al. Reemergence of human monkeypox in Nigeria, 2017. *Emerg Infect Dis* 2018;24(June (6)):1149–51.
- Zumla A, Dar O, Kock R, Muturi M, Ntoumi F, Kaleebu P, et al. Taking forward a 'One Health' approach for turning the tide against the Middle East respiratory syndrome coronavirus and other zoonotic pathogens with epidemic potential. *Int J Infect Dis* 2016;47(June):5–9. doi:<http://dx.doi.org/10.1016/j.ijid.2016.06.012>.
- Zumla A, Ippolito G, McCloskey B, Bates M, Ansumana R, Heymann D, et al. Enhancing preparedness for tackling new epidemic threats. *Lancet Respir Med* 2017;5(August (8)):606–60.

Eskild Petersen^{a,b,c,*}

^aInstitute of Clinical Medicine, University of Aarhus, Denmark

^bThe Royal Hospital, Muscat, Oman

^cESCMID Emerging Infections Task Force, Basel, Switzerland

Ibrahim Abubakar

Institute for Global Health, University College London, London, United Kingdom

Chikwe Ihekweazu

Nigeria Centre for Disease Control, Jabi, Abuja, Nigeria

David Heymann

Faculty of Epidemiology and Population Health, Department of Infectious Disease Epidemiology, London School of Hygiene and Tropical Medicine, London, United Kingdom

Francine Ntoumi

University Marien NGouabi and Fondation Congolaise pour la Recherche Médicale (FCRM), Brazzaville, Congo

Lucille Blumberg

National Institute for Communicable Diseases, Johannesburg, South Africa

Danny Asogun

Department of Public Health, Faculty of Clinical Sciences, College of Medicine, Ambrose Alli University, Ekpoma, Nigeria

Victor Mukonka

Zambia National Public Health Institute, Ministry of Health, Lusaka, Zambia

Swaib Abubaker Lule

Institute for Global Health, University College London, London, United Kingdom

Matthew Bates^{a,b}

^aHerpeZ and UNZA-UCLMS Project, University Teaching Hospital, Lusaka, Zambia

^bSchool of Life Sciences, University of Lincoln, Lincoln, United Kingdom

Isobella Honeyborne

Division of Infection and Immunity, Center for Clinical Microbiology, University College London, London, United Kingdom

Sayoki Mfinanga

National Institute of Medical Research Muhimbili, Dar es Salaam, Tanzania

Peter Mwaba

UNZA-UCLMS Project, and Lusaka Apex University Medical School, Lusaka, Zambia

Osman Dar^{a,b}

^aPublic Health England, London, United Kingdom

^bChatham House Centre on Global Health Security, London, United Kingdom

Francesco Vairo
National Institute for Infectious Diseases, Lazzaro Spallanzani, IRCCS,
Rome, Italy

Maowia Mukhtar
Institute of Endemic Diseases, University of Khartoum, Khartoum,
Sudan

Richard Kock
Department of Pathobiology and Population Sciences, The Royal
Veterinary College, Hertfordshire, United Kingdom

Timothy D. McHugh
Division of Infection and Immunity, Center for Clinical Microbiology,
University College London, London, United Kingdom

Giuseppe Ippolito
National Institute for Infectious Diseases, Lazzaro Spallanzani, IRCCS,
Rome, Italy

Alimuddin Zumla^{a,b}
^aDivision of Infection and Immunity, Center for Clinical Microbiology,
University College London, United Kingdom

^bThe National Institute of Health Research Biomedical Research
Centre at UCL Hospitals, London, United Kingdom

* Corresponding author at: Institute of Clinical Medicine, Uni-
versity of Aarhus, Denmark.

E-mail addresses: eskildp@dadlnet.dk (E. Petersen),
i.abubakar@ucl.ac.uk (I. Abubakar),
chikwe.iheweazu@gmail.com (C. Ihekweazu),
David.Heymann@lshtm.ac.uk (D. Heymann),
ffntoumi@hotmail.com (F. Ntoumi),
lucilleb@nicd.ac.za (L. Blumberg),
asogun2001@yahoo.com (D. Asogun),
vmukonka@gmail.com (V. Mukonka),
swaiblule@gmail.com (S. Lule),
MBates@lincoln.ac.uk (M. Bates),
i.honeyborne@ucl.ac.uk (I. Honeyborne),
gsmfinanga@yahoo.com (S. Mfinanga),
pbmwaba2000@gmail.com (P. Mwaba),
Osman.Dar@phe.gov.uk (O. Dar),
francesco.vairo@inmi.it (F. Vairo),
mmukhtar@tropmedicine.org (M. Mukhtar),
rkock@rvc.ac.uk (R. Kock),
t.mchugh@ucl.ac.uk (T. McHugh),
giuseppe.ippolito@inmi.it (G. Ippolito),
a.zumla@ucl.ac.uk (A. Zumla).