

This is the peer reviewed version of the following article:

Drożdżyńska, M., Monticelli, P., Neilson, D. and Viscasillas, J. (2016), Ultrasound-guided subcostal oblique transversus abdominis plane block in canine cadavers. *Vet Anaesth Analg*. doi:[10.1111/vaa.12391](https://doi.org/10.1111/vaa.12391)

This article may be used for non-commercial purposes in accordance with [Wiley Terms and Conditions for Self-Archiving](#).

The full details of the published version of the article are as follows:

TITLE: Ultrasound-guided subcostal oblique transversus abdominis plane block in canine cadavers

AUTHORS: Drożdżyńska, M., Monticelli, P., Neilson, D. and Viscasillas, J.

JOURNAL TITLE: *Veterinary Anaesthesia and Analgesia*

PUBLISHER: Wiley

PUBLICATION DATE: 27 May 2016 (online)

DOI: 10.1111/vaa.12391

SHORT COMMUNICATION

Ultrasound-guided subcostal oblique transversus abdominis plane (TAP) block in canine cadavers

Maja Drożdżyńska, Paolo Monticelli, David Nelson & Jaime Viscasillas

Royal Veterinary College, Queen Mother Hospital for Animals, Hatfield, Hertfordshire,
UK

Correspondence: Maja Drożdżyńska, Hawkshead Lane, North Mymms

Hertfordshire, AL9 7TA, E-mail: mdrozdzyńska@rvc.ac.uk

Running Head: Subcostal TAP block in canine cadavers

2 **Abstract**

3 **Objectives** To describe the ultrasound-guided transversus abdominis plane (TAP) block using a
4 subcostal oblique approach in dog cadavers and to evaluate the spread of a methylene blue
5 solution using a multiple-injection technique.

6 **Study design** Prospective, descriptive, experimental anatomical study.

7 **Animal population** Nine adult Beagle cadavers weighing 13 ± 2 kg (mean \pm standard deviation)

8 **Methods** Methylene blue solution (10 mL) was injected bilaterally within the fascia that overlies
9 the transversus abdominis muscle of dog cadavers under ultrasound guidance. For each side, a
10 total of 3 injections (3.3 ml each) were performed by the same operator. Dissection was
11 performed by a second operator 20 minutes later. Successful nerve staining was defined as the
12 presence of dye on the nerve with a length greater than 1 cm.

13 **Results** Ventral branches of T9, T10, T11, T12 and T13 nerves innervating the cranial abdominal
14 wall were stained in 72%, 95%, 100%, 95% and 61% of cases, respectively. Ventral branches of
15 L1 and L2 innervating caudal abdominal wall were stained in only 33% and 11% of cases,
16 respectively. The dye was found only in the fascia between the transverses abdominis and the
17 internal oblique muscles.

18 **Conclusions and clinical relevance** The ultrasound-guided subcostal oblique TAP block
19 provided adequate staining of the sensory innervation of the cranial abdominal wall and for this
20 reason further studies are needed to evaluate efficacy of this technique to block the nociceptive
21 response in clinical situations.

22 **Keywords** Cranial abdomen, dogs, regional analgesia, subcostal oblique approach, TAP block,
23 ultrasound guidance.

25 **Introduction**

26 The canine abdominal wall is innervated cranially by the ventromedial branches of T11, T12,
27 T13 nerves and caudally by L1, L2 and L3 nerves (Evans, 1993). The transversus abdominis
28 plane (TAP) block is a regional anaesthesia technique designed to desensitize the nerves
29 innervating abdominal muscles, abdominal subcutaneous tissue and parietal peritoneum. Local
30 anaesthetic must be administered in the fascia between the internal oblique and transversus
31 abdominis muscles where the ventral branches of the spinal nerves are located.

32 In human anaesthesia, several approaches for ultrasound (US)-guided TAP block have been
33 described, such as: subcostal oblique, mid-axillary and posterior approach (Carney et al. 2011).
34 The anterior approach, also known as a subcostal oblique approach, was described by Hebbard
35 (Hebbard 2010). This technique was developed to block ventral branches of T9 to T12 nerves in
36 order to provide somatic analgesia for supraumbilical abdominal surgeries.

37 Several clinical studies have been conducted in human anaesthesia to evaluate the effectiveness
38 of the subcostal oblique approach (Milan et al. 2011; Wu et al. 2013) Its analgesic efficacy and
39 positive impact on postoperative opioid requirements have been proven during liver transplants
40 (Milan et al. 2011) and radical gastrectomies (Wu et al 2013).

41 In veterinary anaesthesia, the posterior approach for US-guided TAP block was described in dog
42 cadavers (Schroeder et al. 2011; Bruggink et al. 2012). Its clinical application has also been
43 demonstrated in one case report in a Canadian lynx (Schroeder et al. 2010) and, with some
44 modification to the technique, in a case series of dogs undergoing surgery for mastectomy
45 (Portela et al. 2014). To the author's knowledge, no studies describing US-guided subcostal TAP
46 block have been published in the veterinary literature. Thus, the objectives of the present study
47 were:

- 48 1) Describe an ultrasound-guided subcostal transversus abdominis plane block

49 technique in dogs.

50 2) Evaluating the spread of methylene blue and individual nerve staining.

51

52 **Materials and methods**

53 Nine thawed canine cadavers (13 ± 2 kg) euthanized for reasons unrelated to the present study
54 were used. The project received ethical approval (URN 2015 1345) from the Royal Veterinary
55 College, London.

56 All sonographic procedures were performed by the same operator (first author) using an
57 ultrasound machine (S9v; Sonoscape, China) with a 25mm linear array transducer (10-6 MHz).
58 An 18 gauge, 68mm Quincke spinal needle (BD Needle, Madrid, Spain) was used. The needle
59 stylet was removed before starting the procedure. The needle was primed with methylene blue
60 (Methylthionium Chloride Injection 1% w/v, Martindale, UK) and remained attached to the
61 syringe while the block was performed.

62 With the cadavers in dorsal recumbency, the abdomen was clipped and spirit (surgical spirit, Vet-
63 Way, UK) with ultrasound gel (Blue ultrasound gel, Henleys Medical, UK) was applied. The
64 transducer was placed initially in a transverse orientation, perpendicular to the linea alba just
65 caudal to the xiphoid process. With the transducer in this position, the following structures could
66 be identified: linea alba, fat within the falciform ligament, part of the rectus abdominis muscle
67 and peritoneum. Rotating the probe by 10-15 degrees with the marker located cranially and
68 therefore positioning it parallel to the costal arch and oblique to midline, allowed visualization of
69 the rectus abdominis muscle (RAM) and the transversus abdominis muscle (TAM). Further, a
70 characteristic sonographic triangle formed by the two hyperechoic linear structures of the
71 peritoneum (deep) and fascia of TAM (superficial) could be found (Figure 1). When these
72 structures were identified, the needle was inserted from the cranial aspect of the transducer, using

73 an in-plane technique, with a 20 ° angle, so that the tip was located in the fascial plane between
74 RAM and TAM.

75 Injection of a liquid within the fascia created a characteristic fluid pocket which opened up the
76 fascia while the volume of fluid increased (hydrodissection). Conversely, if the tip of the needle
77 was placed within the muscle tissue, then spread of the injectate was chaotic and non-uniform.
78 When the investigator was satisfied with the position of the needle, a volume of 3.3 mL of
79 methylene blue was injected. The needle was removed and the hydrodissected fascial plane was
80 followed caudolaterally using the ultrasound image to the point where the fluid pocket
81 terminated. The edge of the fluid pocket was the target for needle placement for the second
82 injection and a further 3.3mL was injected. This lateral tracking and injection was repeated once
83 more, so that a total volume of 10 mL was administered over three points. The same procedure
84 was performed on the contralateral side.

85 Twenty minutes after completion of the procedure, the second investigator(second
86 author)performed dissection of the hemiabdominal walls. Staining of T9 to L2 nerves was
87 assessed and recorded. The nerve was considered successfully stained when dye could be
88 detected over a length greater than 1 cm.

89

90 **Results**

91 Eighteen hemi-abdominal walls of nine adult beagle cadavers were scanned, injected and
92 dissected. The previously described sonographic landmarks required to perform TAP block using
93 this approach were identified in all hemispheres. In all cadavers dye was located only in the
94 transversus abdominal plane.

95 The most cranial spread of the dye was observed at the level of the T9 nerve which was
96 successfully stained in 72% of cases. T10, T11, T12 and T13 were successfully stained in 95%

97 %, 100%, 95% and 61% respectively. L1 and L2 nerves were successfully stained in 33% and
98 11% of cases.

99

100 **Discussion**

101 The results of the present study show satisfactory spread of the dye in the cranial abdominal wall
102 using an ultrasound-guided oblique subcostal approach. Similarly to human studies (Barrington
103 et al 2009), the most cranial distribution of the dye in this approach was reported at the level of
104 the ninth intercostal nerve which, in the current study, was stained in 72% of cases. The success
105 rate of T9 to T13 nerve staining suggests that this technique could be suitable for treatment of
106 somatic pain associated with procedures performed in the cranial abdomen such as liver surgeries
107 (lobectomy, portosystemic shunt occlusion, cholecystectomy), gastrotomy and splenectomy.

108 Nerves L1 and L2 were blocked in less than one-third of the cases. One possible explanation for
109 the lower success rate may be that the volume of dye injected was too small to spread far enough
110 caudally. However, conflicting information regarding the influence of volume on dye spread is
111 found in the literature. Carney et al. (2011) showed in a human study that doubling the volume of
112 solution did not result in more extensive dye spread and that injection site rather than the volume
113 is more important in determining spread. Contrastingly, a positive correlation was found between
114 volume injected and dye spread in dogs (Bruggink et al 2011). Therefore, it is possible that in the
115 present study, caudal abdominal nerves (L1, L2) could have been stained with a higher success
116 rate if dye volume had been increased.

117 When we compared our data to the Schroeder et al. study (2011), which investigated dye spread
118 after posterior TAP approach in canine cadavers, the success rate in staining particular nerves was
119 significantly different between the posterior and subcostal oblique approaches. First, the most
120 cranial spread of dye in Schroeder's study was to the level of T11 which was stained in only 20%

121 of cases, whereas T11 was stained in 100% of cases using the subcostal approach. Furthermore, a
122 more cranial spread of the dye was achieved in our study- T9 and T10 nerves were stained in
123 72% and 95% respectively whereas neither of these nerves were stained using the posterior
124 approach. However, Schroeder et al. had a higher success rate and better spread of dye in the
125 caudal abdomen- T13, L1 and L2 were stained in 100%, 90% and 30% of cases respectively,
126 compared to this study where success rate was 61%, 33% and 11% respectively. Based on these
127 findings, we can postulate that combining the posterior approach described by Schroeder et al.
128 and the subcostal approach described here may be a reasonable option for long abdominal
129 incisions extending from the pre-umbilical to the caudal abdominal region. Portela et al. (2014)
130 who first described the clinical application of posterior TAP block for radical mastectomy in
131 dogs, used two injection sites: cranial to the iliac crest and caudal to the last rib. It is difficult to
132 reach a clear conclusion regarding the cranial extension of this TAP block since intercostal
133 blocks were performed concurrently in order to block the most cranial mammary glands.

134 The injectate volume of 10 mL was based on the only known previously published veterinary
135 study (Schroeder et al. 2011) which allowed for comparison with our results. However in a
136 clinical scenario, the decision about injected volume will be influenced by two factors: toxic
137 dose and the final concentration of the local anaesthetic solution. One must first consider that the
138 toxic dose should not be exceeded, and second that the local anaesthetic should not be diluted
139 below its minimum effective concentration because sensory block may not be achieved.

140 Further clinical studies are needed in veterinary anaesthesia to determine the peak plasma
141 concentration of local anaesthetics following administration for TAP block and to determine the
142 minimum dose needed to achieve satisfactory analgesia.

143 The distribution of the dye in cadavers may not reflect exactly the final distribution of the local
144 anaesthetics in clinical cases. Carney (2011) found that in humans the spread of local
145 anaesthetics within the fascia is time-dependent (Carney et al. 2011). Although this information is

146 not as applicable to the cadaveric study, it may have significant impact on clinical efficacy of the
147 block depending on the time elapsed between performing the block and starting the surgical
148 procedure.

149 In conclusion, US-guided subcostal TAP block may provide somatic analgesia of the cranial
150 abdominal wall in dogs. Clinical studies are needed to evaluate the efficacy of this block in
151 providing perioperative analgesia for patients undergoing cranial abdominal surgery.

152 **Acknowledgements**

153 **Authors' contributions**

154 MD: performed the US-guided TAP blocks, literature overview, manuscript preparation; PM: performed
155 the cadaver dissection and assessment of dye spread, data collection and analysis; DN: manuscript
156 preparation, language corrections; JV: idea provider, teacher, supervisor, manuscript preparation.

157

158

159 **References**

160 Bruggink SM, Schroeder KM, Baker-Herman TL et al. (2012) Weight-based volume of injection
161 influences cranial to caudal spread of local anesthetic solution in ultrasound-guided transversus
162 abdominis plane blocks in canine cadavers. *Vet Surg* 41, 455-457.

163 Carney J, Finnerty O, Rauf J et al. (2011) Studies on the spread of local anaesthetic solutions in
164 transversus abdominis plane blocks. *Anaesthesia* 66, 1023-1030.

165 De Oliveira Gildasio S, Castro-Alves, Jorge L et al. (2014) Transversus Abdominis Plane Block
166 to Ameliorate Postoperative Pain Outcomes After Laparoscopic Surgery: A Meta-Analysis of
167 Randomized Controlled Trials. *AnesthAnalg* 118, 454-463.

168 Evans HE (1993) *Miller's Anatomy of the Dog* (3rd edn). Saunders, Philadelphia, PA. pp. 308–

169 312

170 Hebbard P (2008) Subcostal Transversus Abdominis Plane Block Under Ultrasound Guidance.
171 *AnesthAnalg* 106, 674-675.

172 Milan ZB, Duncan B, Revari V et al. (2011) Subcostal Transversus Abdominis Plane Block for
173 Postoperative Analgesia in Liver Transplant Recipients. *Transplant Proc* 43, 2687-2690.

174 Portela DA, Romano M, Briganti A (2014) Retrospective clinical evaluation of ultrasound
175 guided transverse abdominis plane block in dogs undergoing mastectomy. *Vet AnaesthAnalg* 41,
176 319-324.

177 Schroeder CA, Schroeder KM, Johnson RA (2010) Transversus abdominis plane block for
178 exploratory laparotomy in a Canadian lynx (*Lynx canadensis*). *J Zoo Wildl Med* 41, 338-341.

179 Schroeder CA, Snyder LBC, Tearney CC et al. (2011) Ultrasound-guided transversus abdominis
180 plane block in the dog: an anatomical evaluation. *Vet AnaesthAnalg* 38, 267-271.

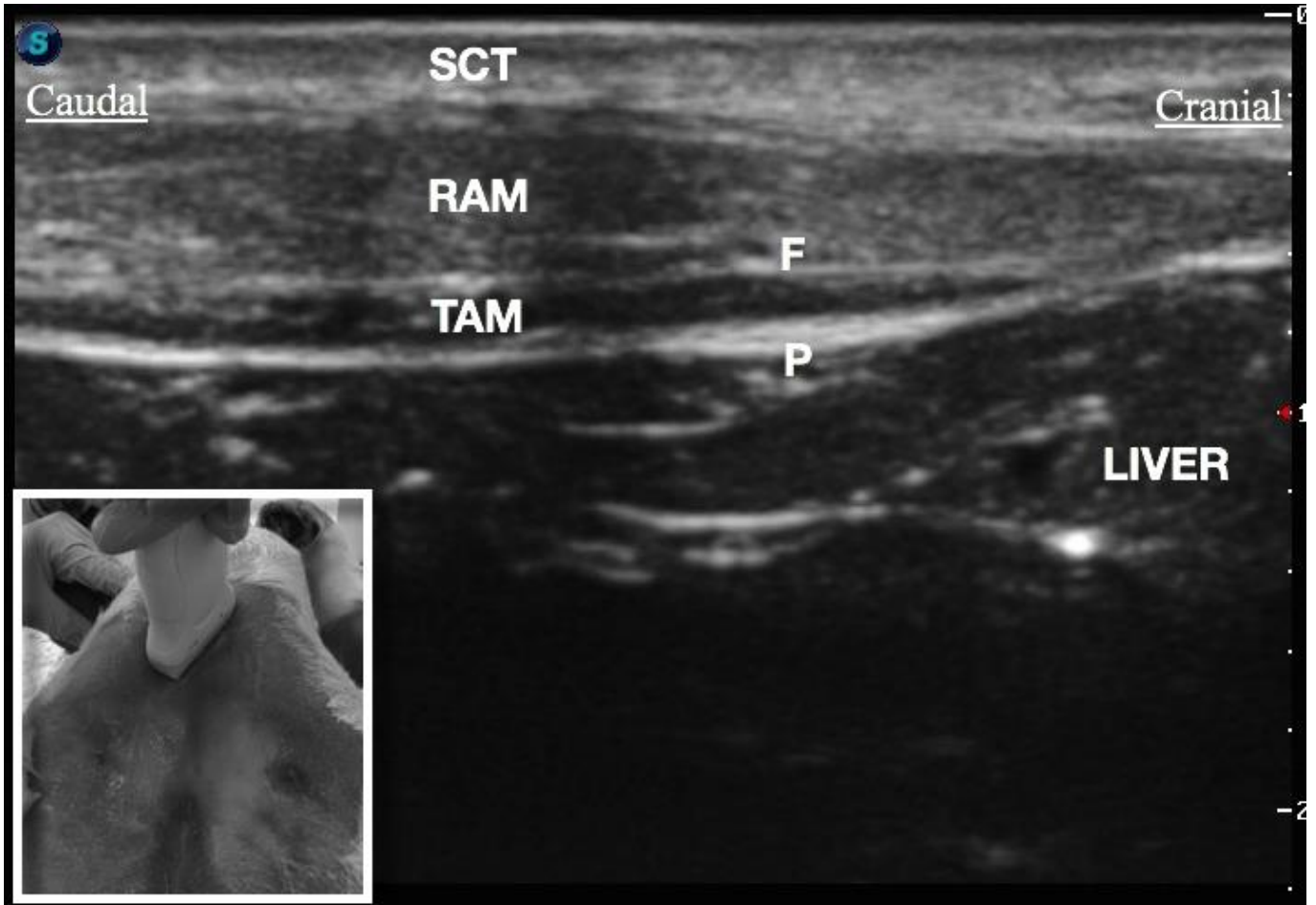
181 Wu Y, Liu F, Tang H et al. (2013) The analgesic Efficacy of Subcostal Transversus Abdominis
182 Plane Block Compared with Thoracic Epidural Analgesia ad Intravenous Opioid Analgesia After
183 Radical Gastrectomy. *AnesthAnalg* 117, 507-513.

184

185 **Figure Legend**

186 SCT- subcutaneous tissue, RAM- rectus abdominis muscle, F-fascia of the transversus abdominis

187 muscle, TAM- transversus abdominis muscle, P- peritoneum.



188